

Case Report

Rhabdomyosarcoma of the mesentery in an infant

Ahmed H. Al-salem^{1*}, Lalit Parida² and Abdulla Al-Wabari²

¹Department of Pediatric Surgery, Maternity and Children Hospital, Dammam, Saudi Arabia.

²Department of Surgery, King Fahad Specialist Hospital, Dammam, Saudi Arabia.

Accepted 23 April, 2013

Rhabdomyosarcoma is the most common soft tissue sarcoma in infants and children. Commonly, it arises from the head and neck, genitor-urinary system, trunk and extremities. Rhabdomyosarcoma arising in the mesentery is extremely rare and only few cases were reported in the literature. This is a case report of a rhabdomyosarcoma of the mesentery in a 4 month-old male infant.

Key words: Rhabdomyosarcoma, mesentery, infant, CT-scan.

INTRODUCTION

Rhabdomyosarcoma originates from undifferentiated mesenchymal cells and can arise at any site in the body. The most common sites are the head and neck, genitourinary system, trunk and extremities (Parham and Ellison, 2006; Ruymann, 1987). Rhabdomyosarcoma was also reported at other unusual sites including the duodenum, fallopian tubes, skin, extrahepatic bile ducts, diaphragm and ampulla of Vater (Parham and Ellison, 2006; Ruymann, 1987; Midorikawa et al., 1998; Federici et al., 1986; Sassi et al., 2008; Zampieri et al., 2006; Caty et al., 1990; Khairy-Shamel et al., 2008; Chang et al., 1990). Primary rhabdomyosarcoma arising from the mesentery is extremely rare with only one case reported in the literature in a child (Agarwal et al., 2003). We report the second case of rhabdomyosarcoma of the mesentery in a 4 month-old child.

CASE REPORT

A 4 month-old male infant was referred to our hospital with an abdominal swelling that was detected incidentally during a routine evaluation for immunization. Clinically, there was a large, firm and mobile abdominal mass occupying most of the abdomen (Figure 1). His CBC, alpha-fetoprotein, serum electrolytes, BUN, creatinine, and liver function tests were normal. Abdominal ultrasound showed an 8.7 × 8.7 × 7.5 cm well defined

lobulated solid abdominal mass occupying the middle of the abdomen. No calcifications were noted. This was confirmed by abdominal and thoracic CT-scan with no evidence of metastatic disease (Figure 2). His bone scan was also normal. The patient underwent an exploratory laparotomy. This revealed a large, nodular, firm and well circumscribed mass arising from the mesentery of the transverse colon (Figure 3). The swelling was adherent to the adjacent colon and so it was resected together with the adjacent colon and primary anastomosis was done. There were also 4 satellite nodules similar to the tumor in the mesocolon (Figure 4). These were excised as well as few mesenteric lymph nodes. The patient had an uneventful post-operative recovery. The histology of the excised mass as well as the satellite nodules showed an embryonal rhabdomyosarcoma of the botryoid subtype arising from the mesentery (Figure 5). The tumor cells were positive for desmin, myoglobin, S-100 protein, and vimentin and negative for muscle actin and CD34 (Figure 6A and 6B). The adjacent colon was not invaded by the tumor and the excised mesenteric lymph nodes were negative for malignancy. The patient was started on chemotherapy (Vincristine + Actinomycin-D + Cyclophosphamide (VAC) regimen) and he is now 18 months post operatively, doing well with no evidence of recurrence.

DISCUSSION

Rhabdomyosarcoma is a common tumor in infants and children with a reported annual incidence of 4.5 cases

*Corresponding author. E-mail: ahsalsalem@hotmail.com

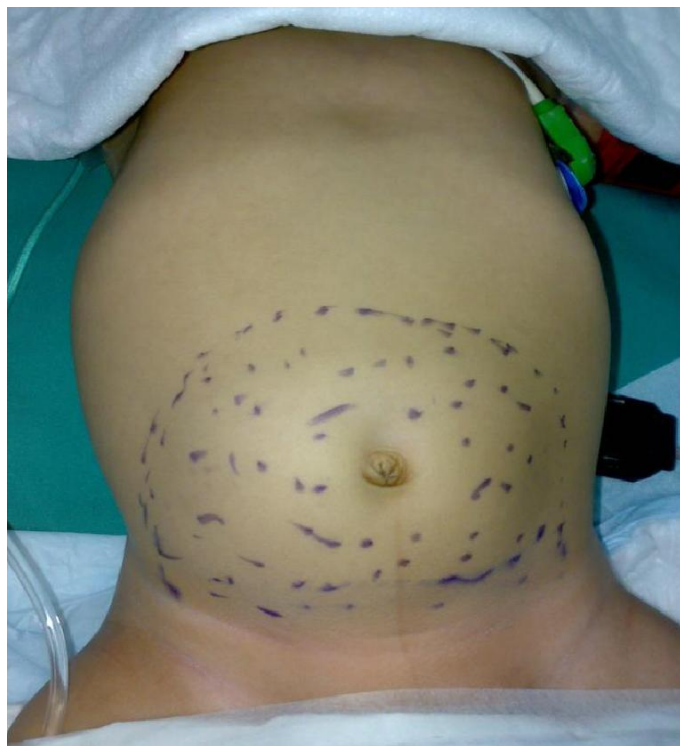

Figure 1. Clinical photograph showing the site and size of the abdominal mass.

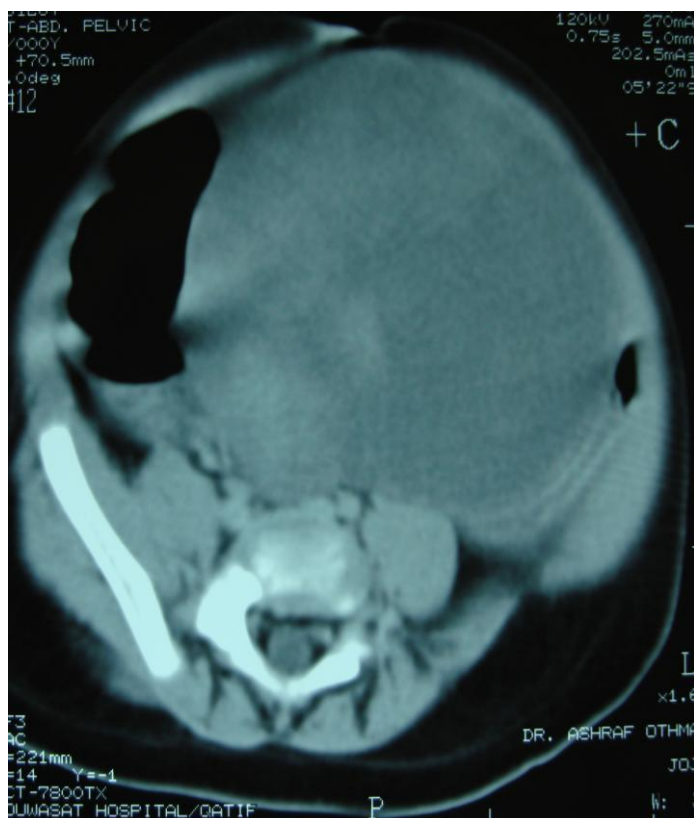


Figure 2. CT- scan of the abdomen showing a large abdominal mass.

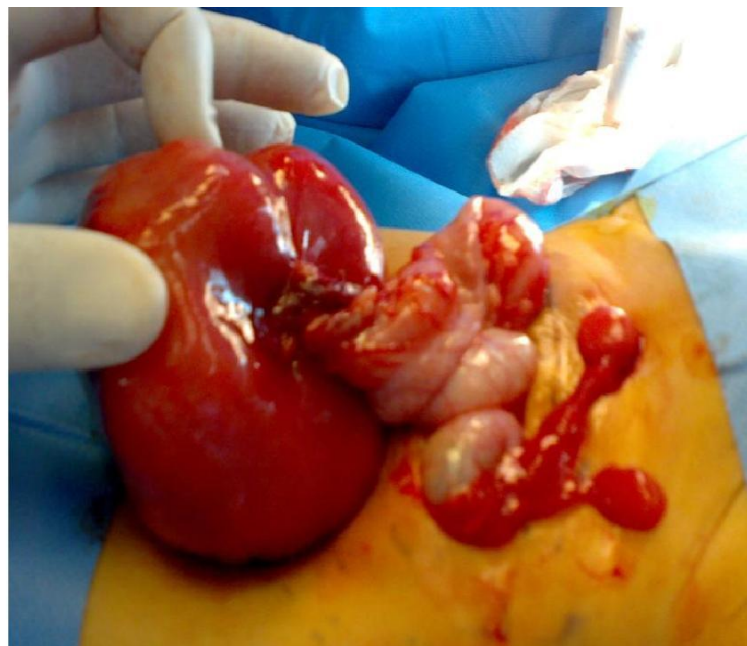

Figure 3. Intra-operative photograph showing a large abdominal tumor. Note its origin from the mesentery and two other satellite tumors in the mesentery.

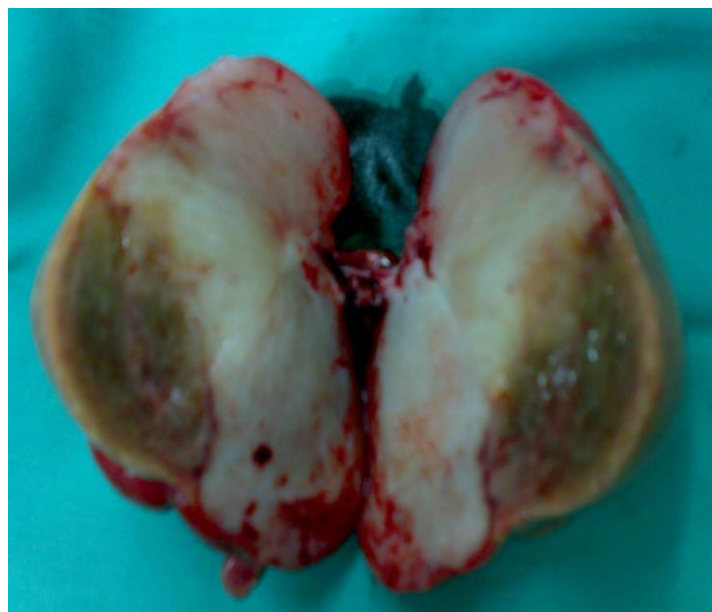

Figure 4. Clinical photograph showing the resected tumor.

per 1 million children younger than 14 years of age (Ries et al., 2003). It represents approximately 3.5% of all malignancies in children aged 0 to 14 years (Cohen, 1992). Rhabdomyosarcoma commonly arise in four major sites which include the head and neck (35 to 40%), genitourinary tract (20%), extremities (15 to 20%) and the trunk (10 to 15%). It has also been reported to arise from

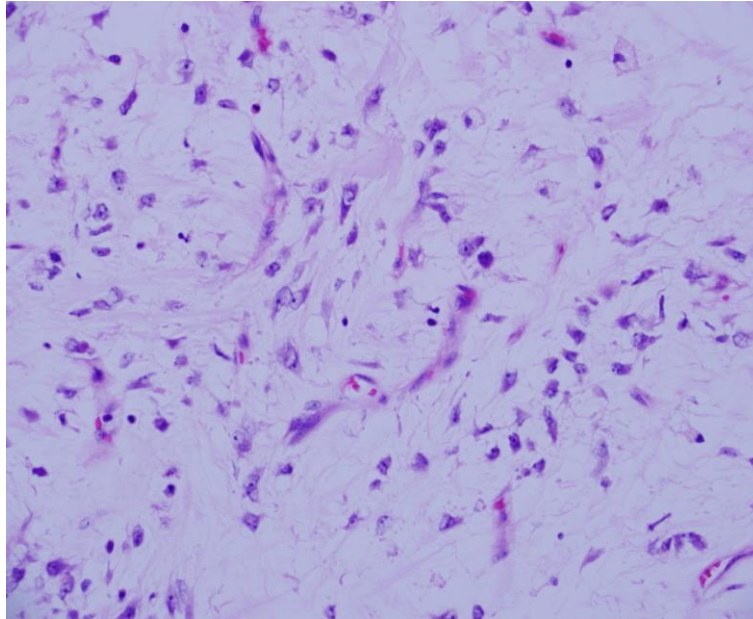


Figure 5. Histological evaluation of the tumor showing cellular, rhabdomyoblasts with myxoid background and few blood vessels and mitotic figures.

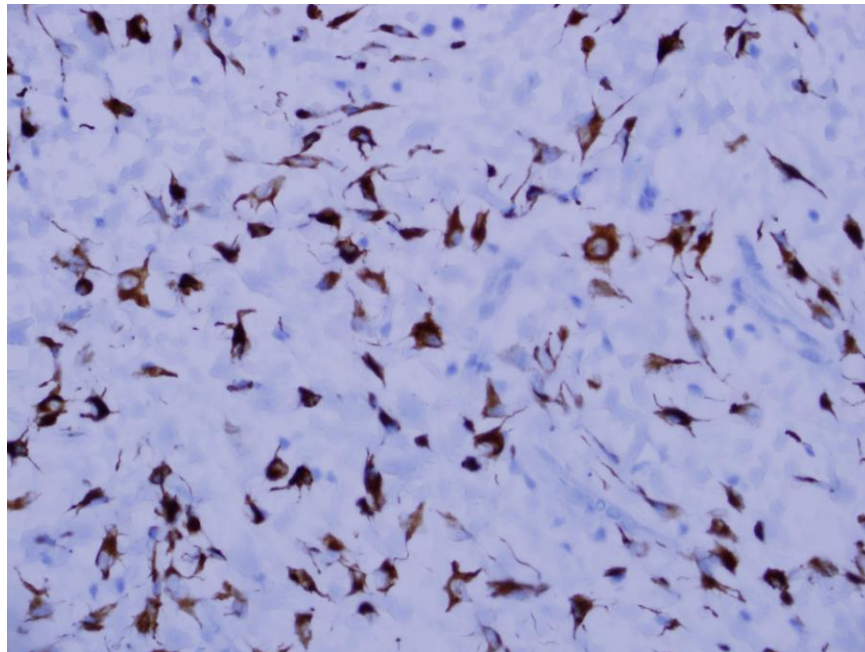


Figure 6A: Histological evaluation of the tumor showing myogenin staining of cytoplasm of rhabdomyoblasts.

and metastasize to nearly all body organs, but intraperitoneal rhabdomyosarcoma usually results from secondary involvement during the course of the disease. In a series of 55 children with rhabdomyosarcomas, the incidence of intraperitoneal involvement was reported as

high as 11% over the course of the disease (Chung et al., 1998). Cecchetto et al. (2003) on the other hand, in a large series of 161 patients with nonmetastatic abdominal rhabdomyosarcomas, reported 32 intraperitoneal, 42 retroperitoneal, 75 pelvic and 12 not otherwise specified.

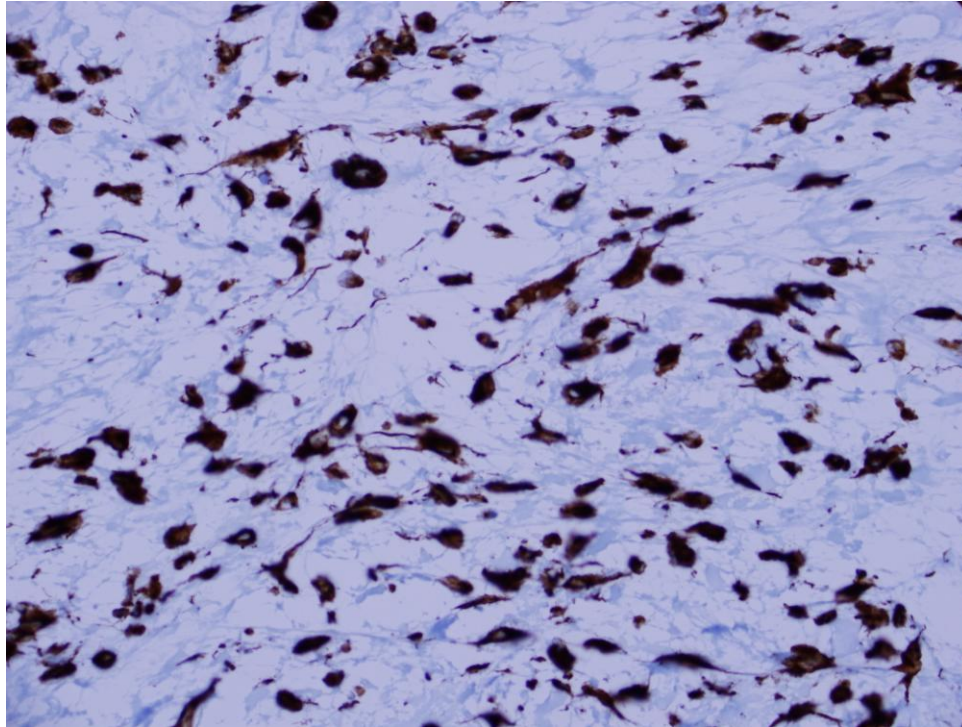


Figure 6B: Histological evaluation of the tumor cells showing vimentin positive marker for mesenchymal origin.

The exact site of origin of the 32 intraperitoneal rhabdomyosarcoma was not however specified. Rhabdomyosarcomas at these sites is considered as part of the intracavitary rhabdomyosarcoma (intraabdominal and intrathoracic rhabdomyosarcoma).

Primary rhabdomyosarcoma arising in the mesentery is extremely rare. Only three cases of primary rhabdomyosarcoma of the mesentery were reported before. Agarwal et al. (2003) reported the only child with a primary embryonal (botryoid) rhabdomyosarcoma of the mesentery. Petit et al. (2001) on the other hand reported primary alveolar rhabdomyosarcoma of the mesentery occurring in a 68 year-old male. Seenu et al. (1995) reported an alveolar rhabdomyosarcoma of the omentum in a 45 year-old male who presented with pyrexia. Kaplan et al. (1999) reported an intra-abdominal embryonal rhabdomyosarcoma in a 57 year-old women but surgical exploration failed to specify the exact site of origin of the tumor. Our patient is the second and youngest case of primary rhabdomyosarcoma of the mesentery to be reported in a child.

There are four main histological types of rhabdomyosarcomas. These include embryonal, alveolar, pleomorphic and undifferentiated or anaplastic (Parham and Ellison, 2006). The botryoid is considered a subtype of embryonal rhabdomyosarcoma arising in mucosal lined body cavities such as the vagina, the urinary bladder, nasopharynx and extrahepatic bile ducts

(Parham and Ellison, 2006; Sassi et al., 2008; Zampieri et al., 2006; Arndt et al., 2001; Arndt et al., 2004; Spunt et al., 2000). In our patient as well as that reported by Agarwal et al. (2003), the histology of the rhabdomyosarcoma was of botryoid type. This is unusual as these tumors are known to arise in mucosal lined body cavities, but on rare occasions they arise from unusual sites such as the conjunctiva and middle ear (Parham and Ellison, 2006; Hawkins et al., 2001; Polito et al., 2006). An interesting feature in our patient was the presence of four small satellite tumors in the mesentery. All showed the same histological features as the primary tumor. It is however, difficult to be certain whether these represent secondary seedings from the original tumor or they are actually multifocal tumors all arising from the mesentery. One point in favour of the multifocal origin is the absence of metastatic disease at any other sites including adjacent lymph nodes. Complete surgical excision of mesenteric rhabdomyosarcoma is the treatment of choice. This will obviate the need for local radiotherapy. In our patient, the tumor was adherent to the wall of the transverse colon, which necessitated excision of part of the transverse colon to achieve complete excision. Regional lymph node sampling is also required.

In conclusion, rhabdomyosarcoma is one of the common tumors seen in infants and children. Rhabdomyosarcoma arising from the mesentery on the

other hand is rare and should be included in the differential diagnosis of malignant primary intraperitoneal neoplasms in infants and children.

REFERENCES

- Agarwal K, Kulshrestha R, Pahuja S, Chadha R (2003). Botryoid rhabdomyosarcoma of the mesentery-a case report. *Indian. J. Pathol. Microbiol.*, 46(3):457-459.
- Arndt C, Rodeberg D, Breitfeld PP, Raney RB, Ullrich F, Donaldson S (2004): Does bladder preservation (as a surgical principle) lead to retaining bladder function in bladder/prostate rhabdomyosarcoma? Results from intergroup rhabdomyosarcoma study iv. *J. Urol.*, 171:2396-2403.
- Arndt CA, Donaldson SS, Anderson JR, Andrassy RJ, Laurie F, Link MP, Raney RB, Maurer HM, Crist WM (2001): What constitutes optimal therapy for patients with rhabdomyosarcoma of the female genital tract? *Cancer*, 91(12):2454-2468.
- Caty MG, Oldham KT, Prochownik EV(1990). Embryonal Rhabdomyosarcoma of the ampulla of Vater with long-term survival following pancreaticoduodenectomy. *J. Pediatr. Surg.*, 25(12):1256-1258.
- Cecchetto G, Bisogni G, Treuner J, Ferrari A, Mattke A, Casanova M, Dall'Igna P, Zanetti I, Volpato S, Siracusa F, Scarzello G, Boglino C, Carli M (2003). Role of surgery for nonmetastatic abdominal rhabdomyosarcoma: a report from the Italian and German soft tissue cooperative groups studies. *Cancer* 97(8):1974-1980.
- Chang Y, Dehner LP, Egbert B (1990). Primary cutaneous rhabdomyosarcoma. *Am. J. Surg. Pathol.*, 14:977-982.
- Chung CJ, Fordham L, Little S, Rayder S, Nimkin K, Kleinman PK, Watson C (1998): Intraperitoneal rhabdomyosarcoma in children: Incidence and imaging characteristics on CT. *ARJ* 170:1385-1387.
- Cohen MD (1992): *Imaging of children with cancer*, 1st ed. St. Louis, Mosby Year Book, 308-337.
- Federici S, Casolari E, Rossi F, Ceccarelli PL, Zanetti G, Mancini A (1986). Rhabdomyosarcoma of the diaphragm in a 4-year-old girl. *Z Kinderchir.* 41(5): 303-305.
- Hawkins DS, Anderson JR, Paidas CN, Wharam MD, Qualman SJ, Pappo AS, Scott Baker K, Crist WM (2001). Improved outcome for patients with middle ear rhabdomyosarcoma: A children's oncology group study. *J. Clin. Oncol.* 19(12): 3073-3079.
- Kaplan AM, Creager AJ, Livasy CA, Dent GA, Boggess JF (1999). Intraabdominal embryonal rhabdomyosarcoma in an adult. *Gynecol Oncol* 74(2): 282-285.
- Khairy-Shamel ST, Shatriah I, Adil H, et al (2008): Orbital rhabdomyosarcoma in an HIV positive child. *Orbit* 2008, 27(8):388-390.
- Midorikawa Y, Kubota K, Mori M, Koyama H, Aihara N, Makuuchi M, Kajura N. (1998). Rhabdomyosarcoma of the diaphragm: Report of an adult case. *Jpn. J. Clin. Oncol.*, 28(3): 222-226.
- Parham DM, Ellison DA (2006). Rhabdomyosarcomas in adults and children: An update. *Archives of Pathology and Laboratory Medicine*, 130(10):1454-1465.
- Petit ML, Leteurtre E, Truant S, Herjean M, Triboulet JP, Lecomte-Houcke M (2001). Alveolar rhabdomyosarcoma: apropos of a rare location. *Ann Pathol* 21(1) 51-54.
- Polito E, Pichierrri P, Loffredo A, Lasorella G (2006). A case of primary botryoid conjunctival rhabdomyosarcoma. *Graefes Arch, Clin, Exp, Ophthalmol.*, 244(40):517-519.
- Ries LAG, Eisner MP, Kosary CL, Hankey BF, Miller BA, Clegg L, Mariotto A, Fay MP, Feuer EJ, Edwards BK (2003). SEER Cancer Statistics Review, 1975-2000. National Cancer Institute, Bethesda, MD, http://seer.cancer.gov/csr/1975_2000, 2003
- Ruymann FB (1987). Rhabdomyosarcoma in children and adolescents: a review. *Hematol Oncol Clin North Am*, 1:621-654.
- Sassi SH, Charfi L, Abbas I, Mrad K, Dhoubi R, Hamida NB, Oubiche F, Barsaoui S, Romdhane KB (2008). Cholestasis caused by a choledochal botryoid rhabdomyosarcoma in a 22- month-old boy. *Ann Pathol* 28(1):45-48.
- Seenu V, Misra MC, Parshad R, Prakash MB (1995). Omental rhabdomyosarcoma presenting with pyrexia. *Indian J. Gastroenterol* 14(1):27-28.
- Spunt SL, Lobe TE, Pappo AS, Parham DM, Wharam MD Jr, Arndt C, Anderson JR, Crist WM, Paidas C, Wiener E, Andrassy RJ, Schwartz CL (2000). Aggressive surgery is unwarranted for biliary tract rhabdomyosarcoma. *J. Pediatr. Surg.*, 35(2): 309-316.
- Zampieri N, Camoglio F, Corroppo M, Cecchetto M, Ornis S, Ottolenghi A (2006): Botryoid rhabdomyosarcoma of the biliary tract in children: a unique case report. *Eur. J. Cancer Care*, 15(5):463-466.