

Case Report

Maternal and Foetal Deaths from Ruptured Spleen Following Abdominal Massage by Traditional Birth Attendants in the Niger Delta, Nigeria

Igberase GO

Department of Obstetrics and Gynaecology, Delta State University Teaching Hospital, Oghara, Nigeria .

ABSTRACT

Abdominal massage is a harmful cultural practice sometimes leading to maternal and Foetal mortality and morbidity. To report a case of maternal and foetal deaths from abdominal massage with review of relevant literature. A case of maternal and fetal deaths from abdominal massage is reported. A case of a 34 year old unbooked gravida 3 para 1+¹ lady admitted at 32 weeks gestation with 2 weeks history of cough and a 3 day history of fever, labour pains and difficulty with breathing is presented. She had abdominal massage done on 2 occasions in a traditional birth attendant's home. Abdominal ultrasound revealed massive intraperitoneal fluid collection with twin intrauterine foetal death. Findings at laparotomy showed a ruptured spleen, massive haemoperitoneum of 4.5 litres and twin intrauterine foetal deaths. She died 2 hours post operatively of hypovolemic shock and cardiac arrest. Widespread public health enlightenment of traditional birth attendants and pregnant women on the harmful effect of abdominal massage is needed.

Key words: Abdominal massage, Splenic rupture, Maternal and Foetal mortalities.

INTRODUCTION

Nigeria has one of the highest maternal mortality statistics worldwide, with rates as high as 2000/10,000 in health institutions^{1,2}. A previous study in this region reported an abdominal massage rate of 14.79% in pregnancy³. A case of abdominal massage in a 34 year old pregnant woman that resulted in maternal and foetal mortalities is hereby reported.

CASE REPORT

Mrs. ED was a 34 year old unbooked gravida 3 para 1+¹ admitted on the 25/12/10 at 32 weeks gestation with 2 weeks history of cough and a 3 day history of fever, labour pains and difficulty with breathing. This was following a referral from a private hospital, having been discharged from a government secondary health facility against medical advice. She resided in a riverine area.

Cough was non-productive, distressing and worse on lying supine. There was no associated chest pain. Fever was high grade and associated with chills and rigors. Labour pains were progressively intense and not associated with liquor drainage. There was no bleeding per vaginam. There was associated difficulty in breathing and upper abdominal pain which was a dull persistent ache, non-radiating.

She had gone to a traditional birth attendant's home 2 weeks prior to presentation for abdominal massage and repeated the same visit 4 days prior to presentation to our hospital.

On examination she was clinically pale with a tinge of jaundice, dehydrated, dyspnoeic and tachypnoeic with bilateral pitting pedal oedema.

Respiratory rate was 30 cycles per minute with few fine crepitations bilaterally in the lower lung zones. The abdomen was enlarged, symphysiofundal height was 42 cm and there was a positive fluid thrill. Her pulse rate was 118 beats per minute and blood pressure was 80/40mmHg. Heart sounds 1 & 2 only were heard. Uterine contractions were not palpable as abdomen was tense. Twin 1 was cephalic. There was a tender hepatomegaly, measuring 6cm below the right costal margin. There was no fetal heart tones heard. Vaginal examination revealed normal female external genitalia. Cervical is was 6cm dilated with a cephalic foetal presenting part at -1 station. A diagnosis of preterm labour with ruptured uterus and anaemic heart failure was made.

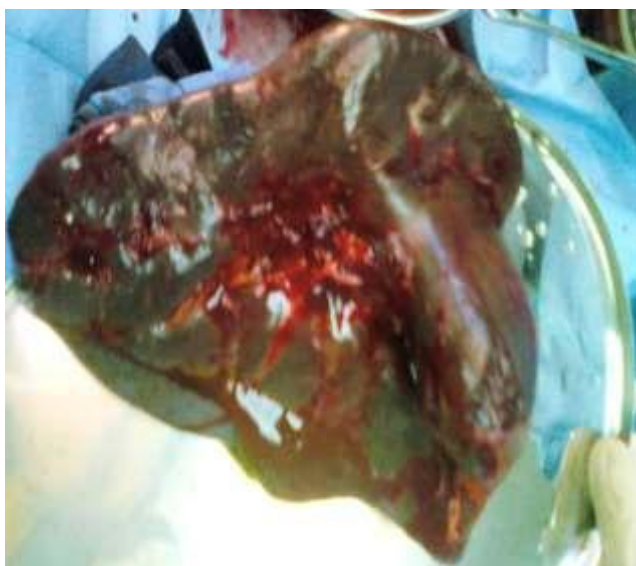
Packed cell volume was 27% and haemoglobin was

8.8g/dl. White cell count was 9,900/mm³, platelet count was 60,000/mm³ and Haemoglobin genotype was HbAA. Liver function test and electrolyte and urea were essentially normal. Malaria parasite was negative. Urinalysis was normal and patient's blood group was O Rhesus D positive. HIV screen was negative. Ultrasound scan revealed twin fetuses with intrauterine foetal death and free peritoneal fluid collection.

She was transfused with a unit of fresh whole blood and also received 500mls of normal saline with intravenous frusemide. Oxygen was administered continuously by face mask and parenteral broad spectrum antibiotics were given. She was catheterized and urinary output was adequate. She was taken for surgery after stabilization.

With the patient under general anaesthesia, routine cleaning and draping done and the peritoneal cavity was accessed via a midline subumbilical incision with

Figure I. Picture showing multiple lacerations on spleen.



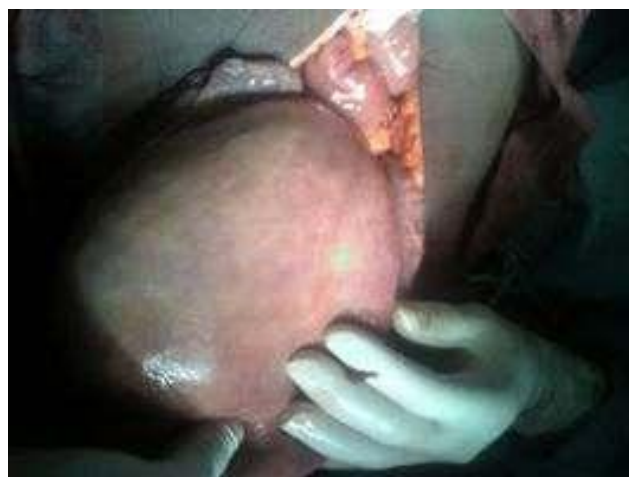DISCUSSION

Maternal and perinatal mortality and morbidity still occurs in alarming proportion in developing countries^{1,2,4}. Maternal mortality is an important indicator of the risks of pregnancy and childbirth, the status of women, and the effectiveness of a health care system. Although maternal mortality rates are lower now than in the past in the developed world, they continue to be a public health concern globally⁵. Among the multitude of causes, poor health seeking behaviour and harmful traditional practices as occurred in this patient are causes. Harmful cultural practices among women of reproductive age occurs commonly in Nigeria^{3,5}. This is a rare case of abdominal massage leading to maternal and foetal

extension to the epigastrium, 4.5 liters of clotted and altered blood was found in the peritoneum, uterus was intact, fallopian tubes and ovaries were apparently normal, twin fresh still births were delivered from the uterus via a lower segment transverse incision. There was a large slab of haematoma covering the spleen, taking the shape of the spleen and multiple lacerations seen on the medial surface of the spleen. Haemoperitoneum was sucked out and a splenectomy was done. Haemostasis was secured. The uterine incision closed also. Peritoneal lavage was done and abdomen closed with interrupted nylon 3/0 to skin. She was further transfused with 2 units of available blood. She died 2 hours after surgery from hypovolaemic shock and cardiac arrest.

wastages. Very few studies have been done on the harmful effects of

Figure II. Picture showing intact uterus.



abdominal massage in pregnancy^{3,5}. Though there are no exact statistics on abdominal massage in pregnancy in the Niger Delta region, practical experience by the author has shown that it is highly prevalent among booked and unbooked women in this region. One study in this region showed a maternal mortality rate of 4.76% while the perinatal mortality rate was 14.29%³. Majority of deliveries takes place in rural areas, in the homes of traditional birth attendants and consequently maternal deaths are commoner also in rural Nigeria⁷.

Unbooked status is a risk factor for maternal mortality in Nigeria^{1,2}. Mrs ED was unbooked and only visited the hospital when she developed complication from abdominal massage. She presented late to our centre where she would have been salvaged if she had

presented early. The diagnosis of twin gestation was not made until presentation as she was unbooked and did not have an ultrasound scan.

Cases of ruptured spleen in pregnancy from causes such as aneurisms have been documented previously in the literature^{8,9}. Rupture of a splenic artery aneurism is a cause of maternal and foetal mortality. Rupture of the spleen can occur even with minimal trauma to the maternal abdomen.

She died of haemorrhagic shock as there was no blood available for further transfusion. Haemoperitoneum consisted of altered blood and clots and this could not be auto transfused.

The menace of abdominal massage in pregnancy is prevalent in the Niger Delta of Nigeria though largely underreported. Widespread public health campaign should be carried out especially in the rural areas with the hope of dissolving the beliefs and myths associated with abdominal massage in pregnancy. Accessibility to well equipped health facilities, education and provision of emergency obstetric care is imperative if we are to reduce this great scourge of our time.

ACKNOWLEDGEMENT

My sincere thanks to my colleagues Drs Duncan Umukoro, Pedro Diken and Zinny Mudiaga for their assistance.

REFERENCES

1. Igberase GO, Ebeigbe PN. Maternal mortality in a rural referral hospital in the Niger Delta, Nigeria. *J Obstet Gynaecol*. 2007;27(3):275-8.
2. Umeora OUJ, Ejikeme BN. Clinical correlates and trends in hospital maternal mortality in rural Nigeria. *J Obstet Gynaecol*. 2006 Feb; 26(2):139-140.
3. Ugboma HA, Akani CI. Abdominal massage: another cause of maternal mortality. *Niger J Med*. 2004;13(3):259-62.
4. Umeora OUJ, Egwuatu VE. The role of unorthodox and Traditional birth care in maternal mortality. *Trop Doct* 2010;40:13-17.
5. Amakiri CT, Akani C. Traumatic injuries in the newborn from abdominal massage in pregnancy. *Nig Jnl Orthopaedics & Trauma* 2003;2(2): 137-139.
6. Wong AB Etches DJ. Maternal mortality in the British Columbia 1987 - 2004. *BC M J* 2006;48(2):76-80.
7. Itina SM. Characteristics of traditional birth attendants and their beliefs and practices in the Offot Clan, Nigeria. *Bull World Health Organ*. 1997;75(6):563-7.
8. El-Shawarby SA, Franklin O, South M, Goodman J. Caesarean splenectomy for spontaneous rupture of splenic artery aneurysm at 34 weeks gestation with survival of the mother and the preterm fetus. *J Obstet Gynaecol* 2006;26:468-9.
9. Asfar FA, Piyaray MS. Awadhi DNA. Rupture of splenic artery aneurysm during Labor: A case report of maternal and fetal survival. *Med Princ Pract* 2005;14:53-4.