

Full Length Research Paper

Influence of some micronutrients and *Citharexylum quadrangular* extract against liver fibrosis in *Schistosoma mansoni* infected mice

Shadia M. Kadry¹, Azza M. Mohamed^{2,3,*}, Ebtehal M. Farrag² and Dalia B. Fayed²

¹Women's College for Arts, Science and Education, Egypt.

²Therapeutic Chemistry Department, National Research Center, Dokki, Egypt.

³Biochemistry Department, Faculty of Science for Girl's, King Abdulaziz University, Jeddah- Kingdom of Saudi Arabia.

Accepted 7 August, 2012

Despite effective chemotherapy, schistosomiasis remains the second major public health problem in the developing world, second to malaria. The present study was undertaken to explore the therapeutic effect of the micronutrients (vitamin E and selenium) and chloroform extract of *Citharexylum quadrangular* leaves and their mixture against the deleterious pathological impacts induced in mice livers by *Schistosoma mansoni* infection. Parasitological markers showed that oral ingestion of the different supplements to *S. mansoni* infected mice was effective in reducing the worm burden with concomitant decrease in the egg burden, granuloma count and its diameter as well as total area of infection in their livers versus untreated ones. Parasitological parameters were reflected by the improvement of the histopathological pictures of livers of infected-treated mice. The current investigation also showed that the used agents and their mixture successfully modulated liver fibrosis of infected mice which was documented by a marked decrease of liver hydroxyproline level (as biomarker of liver fibrosis) as well as the serum levels of inflammatory fibrogenic mediators namely, fructosamine, tumor necrosis factor alpha (TNF α) and total immunoglobulin E (IgE). In addition, the used agents showed ameliorative action on the elevated liver oxidative stress- nitric oxide (NO) and malondialdehyde (MDA) and the decreased antioxidant biomarkers, reduced glutathione (GSH), glutathione reductase (GR), thioredoxin reductase (TrxR) and catalase (CAT) which may have a role in liver damage and fibrosis due to *S. mansoni* infection. In conclusion, treatment with the used micronutrients and plant extract either alone or in combination attenuated the deleterious impacts of *S. mansoni* infection on mice livers. The combination of all supplements was more effective as it greatly modified the inflammatory mediators and oxidative stress responsible for schistosomal liver fibrosis.

Key words: *Citharexylum quadrangular*, Vitamin E, selenium, *Schistosoma mansoni*, antioxidants.

INTRODUCTION

Schistosomiasis is a chronic parasitic disease caused by blood flukes (trematode) of the genus *Schistosoma*. Schistosomiasis is prevalent in tropical and sub-tropical areas, especially in poor communities without access to

safe drinking water and adequate sanitation. It is estimated that at least 90% of those requiring treatment for schistosomiasis (230 million people) live in Africa (WHO, 2012).

*Corresponding author. E-mail: luoyonghuang@126.com. Tel: +86 23 13883808688. Fax: +86 23 68251048.

Among the five different schistosome species, *Schistosoma mansoni* is the most abundant one in Egypt (Helmy et al., 2009). Pathology associated with *S. mansoni* results primarily from the accumulation of parasite eggs giving rise to hepatomegaly that may be superseded by extensive liver fibrosis (Gryseels et al., 2006). Schistosomiasis causes a reduction in the levels of protective endogenous antioxidants and increases generation of free radicals (El-Shenawy et al., 2008) that leads to a state of oxidative stress (Abdallahi et al., 1999).

Chemotherapy is one of the most effective methods for controlling this disease (Amer and Kamel, 2002). Praziquantel is virtually the only drug available and advocated by the World Health Organization (Doenhoff et al., 2009). The extensive use and reliance on one single drug have raised concerns about the emergence of resistance (Botros and Bennett, 2007; Caffrey, 2007). Therefore, there is growing consensus that novel antischistosomal drugs should be discovered and developed (Keiser, 2010).

Because of the great need to develop new antischistosomal agents, trials were designed to test the potency of traditional medicinal plants for treating schistosomiasis. Some medically important plant species rather show an effect against schistosomiasis (Allam, 2009; Kamel et al., 2011). *Citharexylum quadrangular*

Jacq (Verbenaceae) is a tree- type ornamental plant widely distributed in many gardens in Egypt. *C. quadrangular* is used in traditional medicine as diuretic, antipyretic and for treatment of liver disorders (Wegner and Wolff, 1977). The biological screening of 70% aqueous ethanolic extract revealed a significant antiulcer, antihypertensive and a hepato-proactive effect (Khalifa et al., 2002). El-Naggar (2007) studied *in vitro* the antischistosomal effect of different extracts of *C. quadrangular* and observed that the chloroform extract and the isolated compounds exhibited potent schistosomicidal, cercaricidal and miracidicidal activities. In addition, it exerts potent action on worms biochemical parameters making it a promising antibilharzial drug.

Recently, interest has grown in the role of natural antioxidants used as a strategy to prevent oxidative damage in the pathophysiology of various health disorders (Khan et al., 2010). Among antioxidants, selenium (Se) and vitamin E (Vit. E), used as micro-nutritional supplements, are the essential elements in almost all biological systems. Studies showed the benefits of supplementation of Vit. E and Se, on host defense against gastrointestinal nematode infection (Au Yeung et al., 2005).

The present study was therefore undertaken to investigate the therapeutic effect of Vit. E, Se and chloroform extract of *C. quadrangular* leaves each alone and their combination against the deleterious pathological impacts induced in mice livers by *S. mansoni* infection.

MATERIALS AND METHODS

Chemicals

All chemicals used were of high analytical grade, products of, Fluka, Sigma and Aldrich Co. (St. Louis, MO, USA).

Plant collection

Leaves of *C. quadrangular* Jacq (family: Verbenaceae) were collected (April, 2010) from the Zoo, Giza, Egypt. It was identified by Mr. Mahmoud Yosery, general manager and head specialists of plant taxonomy, Giza Zoo, Egypt.

Plant extraction

The lyophilized dried powdered leaves were extracted exhaustively in a Soxhlet apparatus using the following successive solvents with increasing polarities: Petroleum ether (40 to 60°C) followed by chloroform. After complete extraction, the chloroform solvent was evaporated to dryness under vacuum at 40°C yielding semisolid free chloroform extract residue.

Animals

Swiss albino female mice CDI strain (18 to 22 g) were selected and maintained throughout the experiment in the Schistosome Biological Materials Supply Program, Theodor Bilharz Research Institute (SBSP/TBRI), Giza, Egypt. Mice were kept in a controlled environment of air and temperature with access to water and diet *ad libitum*. This study was conducted in accordance with legal ethical guidelines of the Medical Ethical Committee of the National Research Center, Dokki, Egypt (approval no. 09210).

Safety study of plant extract

Thirty six mice were divided into 6 groups (6 mice each) for determination of chloroform extract of *C. quadrangular* leaves safety. Six doses (500 to 5000 mg/Kg) were suspended in corn oil and orally administrated to mice. A concurrent control group of untreated mice was used. Twenty four hours post oral administration, the mice in different groups were observed for mortality (Kumar, 2012).

Parasites and Infection

Cercariae of *S. mansoni* Egyptian strain were obtained from SBSP/TBRI and used for infection immediately after shedding from *Biomphalaria alexandrina* snails. Infection was carried out with 75 ± 5 *S. mansoni* cercariae/ mouse by subcutaneous injection (Holland et al., 1974).

Experimental design

Sixty normal female mice were divided into 6 equal groups as follow:

- G1 normal healthy animals,
- G2 *S. mansoni* infected mice,
- Groups 3 to 6: *S. mansoni* infected mice treated with Vit. E, Se and

plant extract each alone or in combination.

All the studied agents were suspended in corn oil and given orally to the infected groups six weeks post infection using the following doses, Vit. E : 100 mg/Kg B.wt/day for two weeks (El-Demerdash, 2004), Se: 200 µg/Kg B.wt/day for two weeks (El-Demerdash, 2004), plant extract 500 mg/Kg B.wt /day for two weeks. The combination of all supplements was given to infected mice using the same above dose for each one. Normal healthy and *S. mansoni* infected mice were orally treated with corn oil daily for two weeks.

At the end of the experiment (8 weeks after infection), animals in each group were anesthetized with ether and blood was collected for serum separation. Serum was separated by centrifugation at $3000 \times g$ for 10 min at 4°C and used for biochemical serum analysis. After liver perfusion, the livers from different animal groups were immediately removed weighed and washed using chilled saline solution. The livers were minced and homogenized in either 10% trichloroacetic acid (for NO and MDA determination) or in ice cold bi-distilled water to yield 10% homogenates using a glass homogenizer. The homogenates were centrifuged for 15 min at $10000 \times g$ at 4°C and the supernatants were used for the biochemical tissue analysis.

Liver perfusion

Worms were recovered from the hepatic portal system by perfusion technique (Smithers and Terry, 1965). The worms from each mouse were left to sediment for about 20 min in a small Petri dish and counted under light microscope. The degree of protection or the percentage of reduction after challenge was calculated as follows: $P = C - V/C \times 100$, where P is the percentage protection, C is the mean number of the parasites recovered from untreated infected mice and V is the mean number of the parasites recovered from treated infected mice.

Tissue egg burden

The number of eggs/g tissue (liver and intestine) was assessed following digestion with 4% KOH (Kamel et al., 1977).

Histopathology and granuloma measurements

Representative slices from liver tissue were taken from the animals of different groups and fixed in buffer formalin (10%). Paraffin embedded sections (4 µm thick) were taken after fixation and slides were stained using haematoxylin and eosin (H and E) by the method of Hirsch et al. (1997). Counting of granulomas was carried out according to Mahmoud and Warren (1974).

Serum biochemical analyses

Fructosamine (FA) (Burtis and Ashwood, 1996), ALT (Bergmeyer et al. 1986), γ - GT (Persijn and van der Slik ,1976) and Albumin (Dumas et al. 1971) were estimated in different experimental groups. TNF α and total IgE were determined using commercial ELISA kits in accordance with the manufacturer's instructions.

Tissue biochemical analyses

The hepatic hydroxyproline content (Jamall et al., 1981), NO (Moshage et al., 1995) and MDA (Ruiz-Larrea et al., 1994) were measured in livers of different experimental groups. The levels of antioxidant markers: GSH (Moron et al., 1979), GR (Erden and Bor, 1984), TrxR (Holmgren and Björnsstedt, 1995) and CAT (Lubinsky

and Bewley, 1979) were estimated in the liver tissue homogenate of the tested and control groups

Statistical analysis

The results were presented as mean \pm standard deviation (S.D.) of 10 mice in each group. Results were analyzed statistically by one way analysis of variance (ANOVA) using statistical package for the social sciences, (SPSS) version 9 software followed by post-hoc test at least significance difference between groups at $p < 0.05$.

RESULTS

Oral safety study

No mortality or clinical signs of toxicity were observed on administration of chloroform extract of *C. quadrangular* leaves to normal healthy mice on using doses up to 5000mg/Kg body weight after 24 hours of plant extract ingestion.

Effect of different supplements on parasitological parameters

Treatment of *S. mansoni* infected mice with Vit. E, Se, plant extract and their combination caused significant decreases in worm burden (53.26, 54.89, 59.78 and 60.32%, respectively) and total ova count (49.95, 51.67, 55.2 and 57.12%, respectively) compared to infected untreated mice (Figure 1). The number of granuloma significantly decreased by 22.52, 7.19, 37.85 and 28.49%, respectively while its diameters decreased by 11.29, 8.18, 15.1 and 17.98%, respectively (Table 1) versus infected untreated mice. The decrease in numbers and diameters of granuloma were coupled with a reduction in total area of infection compared with infected mice (31.63, 15.11, 47.33 and 41.47%, respectively) (Figure 1).

Effect of different supplements on liver histopathology

S. mansoni infected liver showed large granuloma and excess inflammation cells (Figure 2b) compared to normal liver section (Figure 2a). Treatment with Vit. E, Se, plant extract or their combination recorded modulating granuloma with a trapped or disintegrating central *Schistosoma* eggs (Figures 2c, d, e, f and g) .

Effect of different supplements on liver biochemical parameters

The results revealed that infection with *S. mansoni* led to elevation of liver hydroxyproline over normal control animals (Figure 3a). Administration of Vit. E, Se, plant

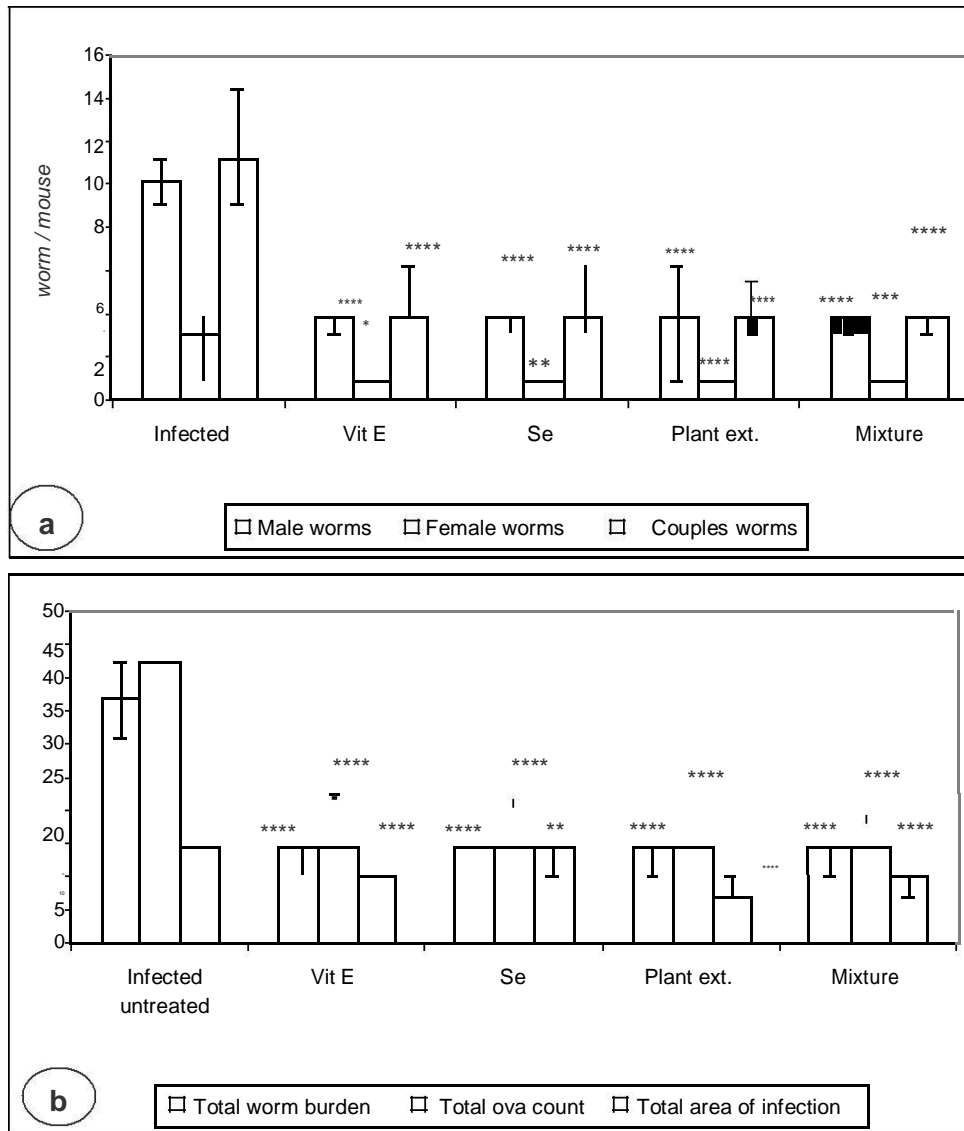


Figure 1. Changes of worm burden, total ova count and total area of infection in different treated groups as compared to infected mice. Data are mean \pm SD of 10 mice in each group. Total ova count is expressed as mean \times 1000 (No. of ova/gm). Total area of infection is expressed as mean \times 100 (μ m/LPF). LPF: Low power field of the microscope. **** $P \leq 0.0001$, *** $P \leq 0.001$, ** $P \leq 0.01$, * $P \leq 0.05$ when compared with infected untreated group.

extract or their combination markedly reduced the level of this biomarker by 30.6, 29.62, 41.17 and 40.23%, respectively, from that of mice in the infected untreated group. Infection with *S. mansoni* recorded a marked decrease in the levels of hepatic enzymatic antioxidants; GR, TrxR, CAT ($P \leq 0.0001$) compared to control groups.

The decrease in GR was associated with a decrease in hepatic non-enzymatic antioxidant, GSH (Table 2). Treatment with the current agents either alone or in combination, markedly increased the antioxidant levels \leq as compared to infected animals. Regarding NO and

MDA, *S. mansoni* infection induced elevation in their levels as compared with normal mice (Figure 3 c, $P 0.0001$). Ingestion of Vit. E, Se, plant extract or their combination, successfully ameliorated the changes that occurred in these markers in relation to infected animals.

Effect of different supplements on serum biochemical parameters

The present data showed that infection with *S. mansoni* induced significant elevation in the levels of serum ALT,

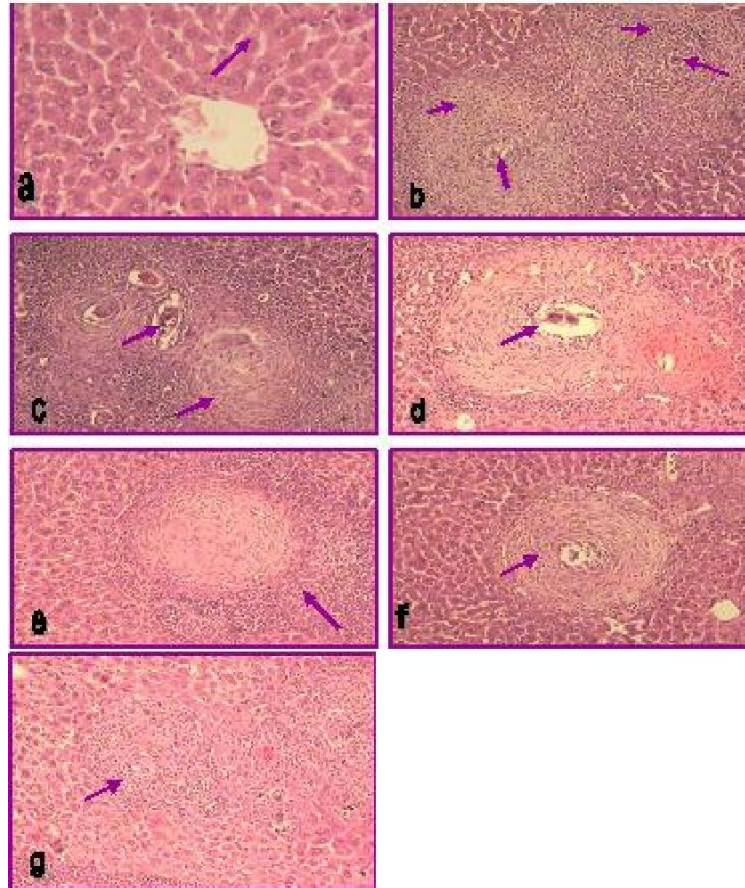


Figure 2. Photomicrograph of liver sections. (a) Normal liver; (b) infected, exhibiting large granuloma with excess inflammatory cells and central schistosome egg; (c) Vit. E treated liver, showing modulating granuloma with a disintegrating central egg and multinucleated giant cells surrounded by inflammatory cells; (d) Se group showing hepatic granuloma with a trapped egg, accumulation of inflammatory cells; (e, f) plant extract treated liver, exhibiting granuloma with or without egg, accumulation of inflammatory cells and normal hepatocytes; (g) All agents treated group showing small hepatic granuloma with a trapped or without egg and accumulation of inflammatory cells. (H and E \times 300).

GGT, fructosamine, TNF- α and total IgE coupled with a reduction in albumin level as compared to normal mice (Table 3 and Figure 3 b). Oral administration of Vit. E, Se, plant extract and their combination to *S. mansoni* infected mice significantly modulated the alteration in the above mentioned biomarkers in comparison to infected mice control group.

DISCUSSION

The emerging evidence for praziquantel tolerance and resistance has prompted the search for novel drugs or combinations of drugs for the treatment of schistosomiasis (Caffrey, 2007). The present study was therefore undertaken to investigate the therapeutic effect

of vitamin E, Se, chloroform extract of *C. quadrangular* or their combination on *S. mansoni* infectivity and its complications in mice.

The results of the present study demonstrated that oral ingestion of Vit. E, Se, plant extract or their combination to infected mice was effective in reducing worm burden and egg count when compared with infected untreated mice, indicating their effective antischistosomal action. Some authors demonstrated that the death of the worms due to the treatment with antischistosomal drugs was attributed to metabolic disorders, mechanical destruction and muscular contraction of treated worms (Doenhoff et al., 2002; Ibrahim et al., 2010). The antischistosomal effect of either Vitamin E or Se is in accordance with Farrag et al. (2002, 2005) who attributed this effect to the antioxidant characteristics of the tested elements.

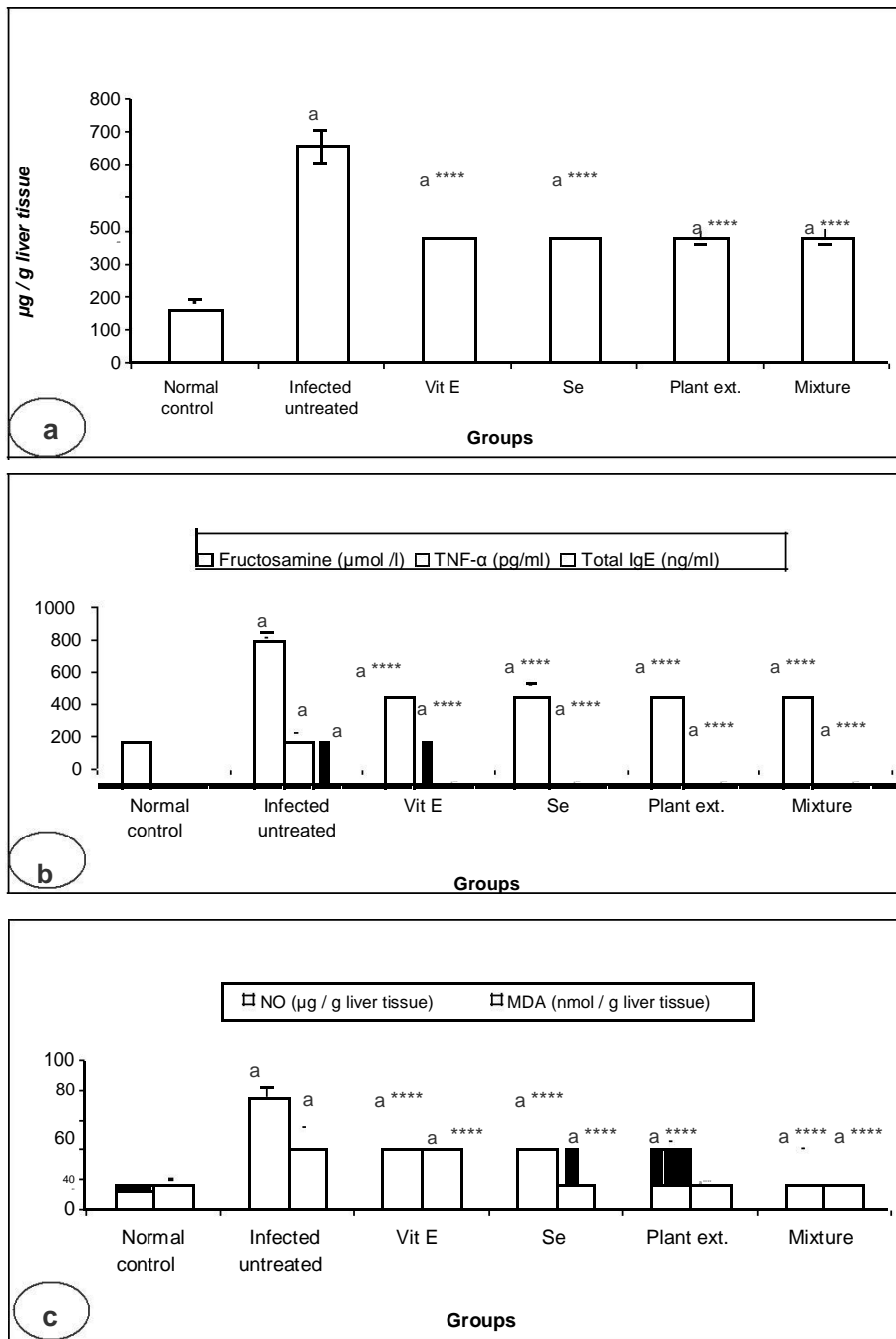


Figure 3. Levels of hepatic hydroxyproline (a), serum inflammatory risk factors (b) and hepatic oxidative stress markers (c) in different infected groups. Data are mean \pm SD of 10 *S. mansoni* infected mice in each group. ^a $P \leq 0.0001$ compared with control group, **** $P \leq 0.0001$ compared with infected group.

Antioxidant supplementations are thought to enhance the immunity of the host to attack the parasite and thereby reduce infectious morbidity and protect the mice from pathogens to a certain level (Farrag et al., 2005). Also, Ali (2007) proved the importance of antioxidants in the treatment of schistosomal infection and reduction of

worm load as well as ova count.

The possible mechanism which may explain the antischistosomal effect of *C. quadrangularis* extract is that it contains active constituents (triterpenes and flavonoidal aglycons) which may have a direct effect on the vitality of schistosome's different stages as well as the fecundity of

Table 1. Parasitological parameters after treatment of *S. mansoni* infected mice with different supplementations.

Parameter group	Number of ova/g		No. of granuloma in liver/	Granuloma diameter
	Liver	Intestine	LPF	(μm)
Infected	24585 \pm 641	18879 \pm 381	7.37 \pm 1.09	232.37 \pm 9.27
Infected treated (Vit. E)	11852 \pm 473 ****	9898 \pm 547 ****	5.71 \pm 1.06 **	206.12 \pm 12.32 ****
Infected treated (Se)	11635 \pm 492****	9369 \pm 492 ****	6.84 \pm 0.91 #	213.35 \pm 13.86 ***
Infected treated (Plant ext.)	11160 \pm 729 ****	8311 \pm 415 ****	4.58 \pm 1.17 ****	197.27 \pm 5.13****
Infected treated (Mixture)	10450 \pm 551****	8186 \pm 623 ****	5.27 \pm 1.11 ****	190.58 \pm 6.12 ****

Data are expressed as mean \pm SD of 10 mice in each group. LPF: Low power field of the microscope (\times 100). **** $P \leq 0.0001$, *** $P \leq 0.001$, ** $P \leq 0.01$, # non significant when compared with infected group.

Table 2. Therapeutic effect of different supplements on the levels of hepatic antioxidant markers.

Parameter group	GR	TrxR	CAT	GSH
Control	90.4 \pm 2.77	36.49 \pm 3.68	18.88 \pm 1	9.82 \pm 0.69
Infected	42.26 \pm 3.33 ^a	9.57 \pm 1.67 ^a	6.1 \pm 0.7 ^a	3.47 \pm 0.4 ^a
Infected treated (Vit. E)	62.97 \pm 1.34 ^a ****	17.21 \pm 1.35 ^a ****	9.02 \pm 1.13 ^a ****	4.03 \pm 0.41 ^a *
Infected treated (Se)	60.22 \pm 2.01 ^a ****	19.15 \pm 2.89 ^a ****	8.41 \pm 0.7 ^a ****	4.11 \pm 0.39 ^a **
Infected treated (Plant ext.)	80.68 \pm 2.73 ^a ****	21.86 \pm 1.24 ^a ****	10.05 \pm 0.59 ^a ****	4.38 \pm 0.28 ^a ****
Infected treated (Mixture)	83.89 \pm 2.65 ^a ****	21.98 \pm 1.2 ^a ****	12.1 \pm 0.85 ^a ****	5.11 \pm 0.31 ^a ****

Data are expressed as mean \pm SD of 10 mice in each group. GR is expressed in nmol/min/mg protein. TrxR and CAT are expressed in $\mu\text{mol}/\text{min}/\text{mg}$ protein. GSH is expressed in $\mu\text{mol}/\text{g}$ tissue. ^a $P \leq 0.0001$ compared with control group, **** $P \leq 0.0001$, ** $P \leq 0.01$, * $P \leq 0.05$ compared with infected untreated group.

Table 3. Therapeutic effect of different supplements on liver function biomarkers in *Schistosoma mansoni* infected mice sera.

Parameter group	ALT (U/L)	GGT (U/L)	Albumin (g / dL)
Control	29.21 \pm 0.84	15.98 \pm 2.03	3.65 \pm 0.45
Infected	91.15 \pm 1.78 ^a	56.69 \pm 2 ^a	0.98 \pm 0.14 ^a
Infected treated (Vit. E)	67.15 \pm 1.15 ^a ****	45.85 \pm 1.24 ^a ****	1.39 \pm 0.12 ^a **
Infected treated (Se)	68.64 \pm 0.92 ^a ****	45.27 \pm 0.71 ^a ****	1.53 \pm 0.13 ^a ****
Infected treated (Plant ext.)	59.61 \pm 1 ^a ****	34.22 \pm 1.06 ^a ****	2.1 \pm 0.15 ^a ****
Infected treated (Mixture)	52.04 \pm 1.1 ^a ****	32.63 \pm 1.02 ^a ****	2.43 \pm 0.3 ^a ****

Data are expressed as mean \pm SD of 10 mice in each group. ^a $P \leq 0.0001$ compared with control group, **** $P \leq 0.0001$, ** $P \leq 0.01$ compared with infected group.

the remaining female adult worms (El-Naggar, 2007). Some authors also documented that the plant extract strongly influence some antioxidant biomarkers (glutathione and glutathione reductase) of adult worms which have an important role in the protection of the parasite against host attack (El-Naggar, 2007; Mohamed et al., 2008). On the other hand, El-Naggar (2007) also proved that extract induce suppressing effect on cholinesterase of adult worm which may lead to its paralysis.

One of the major pathological features of *S. mansoni*

parasites is their ability to persist and establish a chronic infection. This leads to chronic inflammation, which in turn can lead to severe fibrotic modification of infected tissues and organs (Meneghin and Hogaboam, 2007). Previous studies revealed that the intensity of schistosomal infection which represented by the worm burden and egg count increase the degree of liver fibrosis and granulomatous reaction (El-Lakkany et al., 2004).

This is in agreement with the present histopathological findings of *S. mansoni* infected liver which revealed increased number and diameter of granuloma, total area

of infection and extensive fibrous tissue accumulation.

Treatment of infected mice with the current used micronutrients or plant extract either alone or in combination improved the histopathological picture of liver. This was ensured by significant diminution in number and diameters of granulomas, reduction in their fibrotic content accompanied with a reduction in total area of infection as compared with infected mice.

The current investigation revealed that liver fibrosis in response to *S. mansoni* parasitic infection was documented by a marked increase in hepatic hydroxyproline. Hydroxyproline, is an amino acid characteristic of collagen metabolism and used as a marker to express the extent of liver fibrosis (Souza et al., 2005). Similar result was obtained by some authors who emphasized that elevated liver hydroxyproline content was associated with *S. mansoni* infection (Mohamed et al., 2008; El-Lakkany et al., 2012). This may be attributed to that *S. mansoni* egg granulomas contain factors responsible for the elevation of free L-hydroxyproline content in the fibrotic liver (Potter et al., 2003). In addition, previous studies reported that reactive oxygen species (Galli et al., 2005) and products of lipid peroxidation (George et al., 2003) are regarded as triggers that activate hepatic stellate cells, which is the key pathogenic event in liver fibrosis (Gutierrez-Ruiz and Gomez-Quiroz, 2007).

Administration of different supplementations either alone or in combination markedly down-regulate the hepatic hydroxyproline level of infected mice versus infected untreated mice. Plant extract and the combination of all supplementations were the most effective ones revealing their antifibrotic effect. The antifibrotic effect of the used plant extract could be attributed to its active compounds, triterpenes and flavonoidal aglycons (El-Naggar, 2007). Flavonoids and triterpenes exhibited hepato-protective activity, anti-inflammatory and inhibitory effect on liver fibrosis (Wang et al., 2011).

Previous investigations revealed that non-immunologic and immunologic mechanisms play a central role in liver fibrosis (Mohamed et al., 2008). In line with these investigations, the present study showed that *S. mansoni* parasitic infection induced the production of inflammatory fibrogenic mediators which ensured by the increase in serum fructosamine, and TNF- α levels coupled with increase in hepatic NO and MDA (index of lipid peroxidation) levels.

Some publications described in vitro the direct role of glucose and its abnormal metabolism in the development of tissue fibrosis (Huang et al., 1999). Serum fructosamine (abnormal glucose metabolism marker), is a glycosylated protein resulting from spontaneous non-enzymatic condensation of glucose and proteins such as plasma protein (Huang et al., 1999; Misciagna et al., 2004). As albumin is the most abundant protein in serum and contains multiple lysine residues, measurement of

fructosamine is mainly referred to glycosylated albumin (Lapolla et al., 2005). Fructosamine has been recognized as a major cause of tissue fibrosis, as it has a main role in increasing the expression of ECMPs and activating of protein kinase C which has a central role in tissue fibrosis (Hattori et al., 2001).

Depending on the above information and from the present study, it can be suggested that increased serum fructosamine, may be used as a useful marker for liver fibrosis.

The over production of hepatic NO in response to parasitic infection may be considered as one of the risk factors to induce oxidative stress and inflict tissue injury (Harrison, 2002). Excessive NO production was reported to exert various influences on the pathogenesis of tissues (Mohamed et al., 2001). The direct toxicity of NO is enhanced by reacting with superoxide radical to give powerful secondary toxic oxidizing species, such as peroxynitrite (ONOO⁻) which is capable of oxidizing cellular structure and causes lipid peroxidation (Eboumbou et al., 2005), a process leads to membrane damage and correlates positively with tissue fibrosis through inducing fibrogenic cytokines and increasing collagen synthesis (Parola and Robino, 2001).

Besides, it was reported that TNF- α essentially functions as a trophic factor for maintaining adult schistosome viability, it is expressed during egg deposition and has a crucial role in the modulation of granulomatous reaction induced by the eggs (Haseeb et al., 2001). Torben and Hailu (2007) stated that increased level of this inflammatory cytokine after egg excretion may be related to the complications of schistosomiasis. It is capable of inducing tissue injury and fibrosis by inducing reactive oxygen species (ROS) production, lipid peroxidation (Poli, 2000), collagen synthesis, other fibrogenic risk factors (Booth et al., 2004a) and inhibiting matrix metalloproteinases production, the key enzyme in the degradation of collagens (Pender et al., 1998). Over production of TNF- α was found to be associated with high risk of periportal fibrosis and ascites accumulation (Booth et al., 2004b).

Increasing serum level of total IgE in infected mice was observed in the present study. This is supported by previous studies who stated that increased circulating IgE level is a humoral response to egg and adult worm antigens, suggesting that this mechanism might be involved in hepatic pathological patterns (Silva et al., 2004). IgE was reported to have the major role in mast cells stimulation which has a central role in the induction of chronic inflammation (Jayapal et al., 2006) and the progression of hepatic fibrosis by producing fibrogenic inflammatory mediators as well as the components of the ECMPs (Gruber 2003; Shen, 2008).

Accordingly, modulating of the inflammatory risk factors and reducing oxidative stress may be considered as targets for pharmacological or molecular interventions for

the treatment of liver fibrosis in murine schistosomiasis (Lucey et al., 1996).

In the present study, ingestion of Vitamin E, Se, plant extract either alone or in combination to infected mice markedly attenuated the elevation of the inflammatory risk factors; fructosamine, NO, MDA, TNF- α and total IgE. The plant extract as well as the combination of the micronutrients recorded the most potent effect. These observations may give an indication of the anti-glycating, antioxidant, anti-inflammatory and immunomodulating beneficial effects of the used agents. The antioxidant and anti-inflammatory effects of the Vitamin E and Se are supported by the previous studies (Sodhi et al., 2008, Vunta et al., 2008). Also the flavonoid constituent of the used plant extract may be responsible for its modulating effect on inflammatory markers. This is supported by the previous studies of Jayapal et al. (2006) and Tuna et al. (2006) who revealed that flavonoids have long been considered to possess anti-inflammatory and immunomodulatory actions.

Parasitic infection induces oxidative stress in liver due to production of ROS (Abdallahi et al., 1999) and reduces the antioxidant mechanisms (Gharib et al., 1999). In line with some studies, the result of the present work indicated that infection of mice with *S. mansoni* revealed obvious decrease in the non enzymatic antioxidant; GSH, as well as the enzymatic antioxidants including, GR, TrRx, and CAT (Gharib et al., 1999; EL-Sokkary et al., 2002).

Treatment with the current micronutrients either alone or in combination, showed an improvement in the antioxidant biomarkers ensuring the antioxidant ability of these agents (Ben Amara et al., 2011; Mezey et al., 2011)

The present work showed that the inflammatory reactions and tissue damage induced in livers of *S. mansoni* infected mice are ensured by marked increase in serum GGT and ALT levels and a decrease in albumin level (Mohamed et al., 2008; Morais et al., 2010). The increment of such enzymes in serum may be due to the destruction of hepatocytes by the action of toxins of the parasite eggs leading to their release into the circulation (Cheever and Anderson, 1971). The decrease in serum albumin may be due to its glycation by glucose forming fructosamine together with reduction in its synthesis by damaged liver . This is emphasized in the current data by the elevated serum fructosamine level (Mahmoud et al 2002; Mohamed et al., 2008). Hypoalbuminemia is one of the factors responsible for the onset of ascites related to liver fibrosis (Horie et al., 1998).

Supplementation of micronutrients and plant extract either alone or in combination, effectively ameliorated the above serum marker of infected mice. This positive response may be attributed to their ability to protect and stabilize cellular membranes permeability and integrity. This protective action of the used micronutrients is sup-

ported by the previous investigations of Khalifa et al. (2002) and Soudani et al. (2011).

In conclusion, the micronutrients Vit. E and Se as well as *C. quadrangular* extract have multi-functions in attenuating the deleterious impacts of *S. mansoni* infection in mice livers. Their effects are mediated through reduction of ova count, worm burden, granuloma diameter and amelioration of inflammatory mediators, antioxidant defense systems, and liver function biomarkers.

REFERENCES

- Abdallahi OMS, Hanna S, de Reggi M, Gharib B (1999). Visualization of oxygen radical production in mouse liver in response to infection with *Schistosoma mansoni*. *Liver* 19:495–500.
- Ali HF (2007). Evaluation of antioxidants effect of *Citrus reticulata* in *Schistosoma mansoni* infected mice. *Trends Med. Res.* 2(1):37-43.
- Allam G (2009). Immunomodulatory effects of curcumin treatment in murine schistosomiasis *mansoni*. *Immunobiology* 214:712-727.
- Amer N, Kamel M (2002). Tegumental alteration and immunological changes in murine Schistosomiasis *mansoni* after treatment with *Artemisia* extract. *J. Egypt Med.* 26:14-22.
- Au Yeung KJ, Smith A, Zhao A, Madden KB, Elfrey J, Sullivan C, Levander O, Urban JF, Shea-Donohue T (2005). Impact of vitamin E or selenium deficiency on nematode-induced alterations in murine intestinal function. *Exp. Parasitol.* 109:201–208.
- Ben Amara I, Soudani N, Troudi A, Bouaziz H, Boudawara T, Zeghal N (2011). Antioxidant effect of vitamin E and selenium on hepatotoxicity induced by dimethoate in female adult rats. *Ecotoxicol. Environ. Saf.* 74:811–819.
- Bergmeyer HV, Herder M, Rej R (1986). Approved recommendation (1985) on IFCC methods for the measurement of catalytical concentration of enzymes. Part 2. IFCC method for aspartate aminotransferase. *J. Clin. Chem. Clin. Biochem.* 24:497.
- Booth M, Mwatha JK, Joseph S, Jones FM, Kadzo H, Ireri E, Kazibwe F, Kemijumbi J, Kariuki C, Kimani G, Ouma JH, Kabatereine NB, Vennervald BJ, Dunne DW (2004b). Periportal fibrosis in human *Schistosoma mansoni* infection is associated with low IL-10, low IFN- γ , high TNF- α , or low RANTES, depending on age and gender. *J. Immunol.* 172:1295-1303.
- Booth M, Vennervald BJ, Butterworth AE, Kariuki C, Amaganga C, Kimani G, Mwatha JK, Oteda A, Ouma JH, Dunne DW (2004a). Exposure to malaria affects the regression of hepatosplenomegaly after treatment for *Schistosoma mansoni* infection in Kenyan. *BMC Medicine.* 2:36-45.
- Botros SS, Bennett JL (2007). Praziquantel resistance. *Expert Opin. Drug Discov.* 2:S35–S40.
- Burtis CA, Ashwood ER (1996). *Tietz Fundamentals of Clinical Chemistry*, Philadelphia (PA), W.B. Saunders, p.370.
- Caffrey CR (2007). Chemotherapy of schistosomiasis: present and future. *Curr. Opin. Chem. Biol.* 11:433–439.
- Cheever AW, Anderson LA (1971). Rate of destruction of *Schistosoma mansoni* eggs in tissues of mice. *Am. J. Trop. Med. Hyg.* 20:62-68.
- Doenhoff MJ, Hagan P, Cioli D, Southgate V, Pica-Mattoccia L, Botros S, Coles G, Tchuem Tchuenté LA, Mbaye A, Engels D (2009). Praziquantel: its use in control of schistosomiasis in sub-Saharan Africa and current research needs. *Parasitology* 13:1–11.
- Doenhoff MJ, Kusel JR, Coles GC, Cioli D (2002). Resistance of *Schistosoma mansoni* to praziquantel: is there a problem?. *Trans. R. Soc. Trop. Med. Hyg.* 96:465- 469.
- Doumas BT, Watson WR, Biggs HG (1971). Albumin standard and measurement of serum albumin with bromocresol green. *Clinica Chimica Acta.* 31:87-96.
- Eboumbou C, Steghens JP, Abdallahi OMS, Mirghani A, Gallian P, Kappel A, Qurashi A, Gharib B, Reggi MD (2005). Circulating markers of oxidative stress and liver fibrosis in Sudanese subjects at risk of schistosomiasis and hepatitis. *Acta Tropica.* 94:99-106.

- El-Demerdash FM (2004). Antioxidant effect of vitamin E and selenium on lipid peroxidation, enzyme activities and biochemical parameters in rats exposed to aluminium. *J. Trace Elem. Med. Biol.* 18:113–121.
- El-Lakkany NM, Hammam OA, El-Maaway WH, Badawy A, Ain-Shoka AA, Ebeid FA (2012). Anti-inflammatory/anti-fibrotic effects of the hepatoprotective silymarin and the schistosomicide praziquantel against *Schistosoma mansoni*-induced liver fibrosis. *Parasites Vectors* 5:9.
- El-Lakkany NM, Seif El-Din SH, Badawy AA, Ebeid FA (2004). Effect of artemether alone and in combination with grape fruit juice on hepatic drug-metabolizing enzymes and biochemical aspects in experimental *Schistosoma mansoni*. *Int. J. Parasitol.* 34:1405-1412.
- El-Naggar DM (2007). Antibilharzial study of some extracts from *Citharexylum quadrangulare* Jacq. Ph. D. Thesis, Fac. Pharm. Girls, Al- Azhar Univ
- El-Shenawy NS, Soliman MFM, Reyad SI (2008). The effect of antioxidant properties of aqueous garlic extract and *Nigella sativa* as anti- schistosomiasis agents in mice. *Rev. Inst. Med. Trop. Sao Paulo.* 50:29-36.
- El-Sokkary GH, Omar HM, Abdel-Fattah M, Hassanein M, Cuzzocrea S, Retter R (2002). Melatonin reduces oxidative damage and increases survival of mice infected with *Schistosoma mansoni*. *Free Radic. Biol. Med.* 32:319-332.
- Erden M, Bor NM (1984). Changes of reduced glutathion, glutathion reductase, and glutathione peroxidase after radiation in guinea pigs. *Biochem. Med.* 31:217-227.
- Farrag E, Maghraby A, Foda DS (2005). Chemoprophylactic effect of selenium and vitamin E against *Schistosoma mansoni* infected mice. *Egypt Pharm. J.* 4:487-497.
- Farrag E, Mantawy M, Foda DS, Abdel-Ghaffar FA (2002). Role of selenium in protection of mice against *Schistosoma mansoni* infection. *J. Egypt Ger. Soc. Zool.* 39(A):71-87.
- Galli A, Svegliati-Baron G, Ceni E, Milani S, Ridolfi F, Salzano R, Tarocchi M, Grappone C, Pellegrini G, Benedetti A, Surrenti C, Casini A (2005). Oxidative stress stimulates proliferation and invasiveness of hepatic stellate cells via a MMP2-mediated mechanism. *Hepatology.* 41:1074–1084.
- George J, Pera N, Phung N, Leclercq I, Yun Hou J, Farrell G (2003). Lipid peroxidation, stellate cell activation and hepatic fibrogenesis in a rat model of chronic steatohepatitis. *J. Hepatology.* 39:756–764.
- Gharib B, Abdallahi OMS, Dessein H, de Reggi M (1999). Development of eosinophil peroxidase activity and concomitant alteration of the antioxidant defenses in the liver of mice infected with *Schistosoma mansoni*. *J. Hepatology.* 30:594–602.
- Gruber BL (2003). Mast cells in the pathogenesis of fibrosis. *Curr. Rheumatol. Rep.* 5:147–53.
- Gryseels B, Polman K, Clerinx J, Kestens L (2006). Human schistosomiasis. *Lancet* 368:1106–1118.
- Gutierrez-Ruiz MC, Gomez-Quiroz LE (2007). Liver fibrosis: searching for cell model answers. *Liver Int.* 27: 434–439.
- Harrison R (2002). Structure and function of xanthine oxidoreductase: where are we now? *Free Radic Biol. Med.* 33:774-797.
- Haseeb MA, Shirazian DJ, Preis J (2001). Elevated serum levels of TNF-alpha, Stnf-RII in murine schistosomiasis correlate with schistosome oviposition and circumoval granuloma formation. *Cytokine* 15:266-269.
- Hattori Y, Kakishita H, Akimoto K, Matsumura M, Kasai K (2001). Glycated serum albumin-induced vascular smooth muscle cell proliferation through activation of the mitogen-activated protein kinase/extracellular signal-regulated kinase pathway by protein kinase C. *Biochem. Biophys. Res. Commun.* 281:891-896.
- Helmy M, Mahmoud S, Fahmy Z (2009). *Schistosoma mansoni*: Effect of dietary zinc supplement on egg granuloma in Swiss mice treated with praziquantel. *Exp. Parasitol.* 122:310–317.
- Hirsch C, Zouain CS, Alves JB, Goes AM (1997). Induction of protective immunity and modulation of granulomatous hypersensitivity in mice using PIII, an anionic fraction of *Schistosoma mansoni* adult worm. *Parasitol.* 115:21-28.
- Holland JC, Pellegrino J, Cozinelli F (1974). Infection of mice with cercariae, schistosomula of *S. mansoni* by intravenous and subcutaneous routes. *Rev. Inst. Med. Trop. Soc.* 16:132-134.
- Holmgren A, Björnsstend M (1995). Thioredoxin and thioredoxin reductase. *Methods Enzymol.* 252:199–208.
- Horie S, Nagai H, Yuuki T, Hanada S, Nakamura N (1998). Effectiveness of recombinant human serum albumin in the treatment of ascites in liver cirrhosis: evidence from animal model. *Gen Pharmacol.* 31:811-815.
- Huang Z, Willett WC, Colditz GA (1999). Waist circumference, waist: hip ratio, and risk of breast cancer in the Nurses Health Study. *Am. J. Epidemiol.* 150:1316-1324.
- Ibrahim R, Nagy F, Aly E, Mohamed A, El-Assal F, El-Amir F (2010). Effect of Treatment with Antifibrotic Drugs in Combination with PZQ in Immunized *Schistosoma mansoni* Infected Murine Model. *J. Am. Sci.* 6(5):208-216.
- Jamall IS, Finelli VN, Que Hee SS (1981). A simple method to determine nanogram levels of 4-hydroxyproline in biological tissues. *Anal Biochem.* 112:70-75.
- Jayapal M, Tay HK, Reghunathan R, Zhi L, Chow KK, Rauff M, Melendez AJ (2006). Genome-wide gene expression profiling of human mast cells stimulated by IgE or FcεRI-aggregation reveals a complex network of genes involved in inflammatory responses. *BMC Genomics* 7:210-227.
- Kamel IA, Cheever AW, Elwi A, Mosimann JE, Danner R (1977). *S. mansoni* and *S. haematobium* infection in Egyptian technique for recovery of worms at necropsy. *Am. J. Trop. Med. Hyg.* 26:696-701.
- Kamel EG, El-Emam MA, Mahmoud SSM, Fouda FM, Bayaomy FE (2011). Parasitological and biochemical parameters in *Schistosoma mansoni*-infected mice treated with methanol extract from the plants *Chenopodium ambrosioides*, *Conyza dioscorides* and *Sesbania sesban*. *Parasitol. Int.* 60:388–392.
- Keiser J (2010). *In vitro* and *in vivo* trematode models for chemotherapeutic studies. *Parasitol.* 137:589–603.
- Khalifa TI, El-Gendi OD, Ammar HA, El-Naggar DM (2002). Iridoid Glycosides from *Citharexylum quadrangulare*. *Asian J. Chem.* 14:197-202.
- Khan RA, Khan MR, Sahreen S (2010). Evaluation of *Launaea procumbens* use in renal disorders: a rat model. *J. Ethnopharmacol.* 128:452–461.
- Kumar G, Srivastava A, Sharma SK, Gupta YK (2012). Safety evaluation of an Ayurvedic medicine, Arogyavardhini vati on brain, liver and kidney in rats. *J. Ethnopharmacol.* 140(1):151-160.
- Lapolla A, Traldi P, Fedele C (2005). Importance of measuring product of nonenzymatic glycation of proteins. *Clin. Biochem.* 38:103-115.
- Lubinsky S, Bewley GC (1979). Genetics of catalase in *Drosophila melanogaster*: Rates of synthesis and degradation of the enzyme in flies aneuploid and euploid for the structural gene. *Genetics* 91:723-742.
- Lucey DR, Clerici M, Shearer GM (1996). Type 1 and type 2 cytokine dysregulation in human infectious, neoplastic and inflammatory diseases. *Clin. Microbiol. Rev.* 9:532-562.
- Mahmoud MR, El-Abhar HS, Saleh S (2002). The effect of *Nigella sativa* oil against the liver damage induced by *Schistosoma mansoni* infection in mice. *J. Ethnopharmacol.* 79:1-11.
- Mahmoud AAF, Warren KS (1974). Anti-inflammatory effect of tartaremetic and niridazole suppression of *schistosoma* egg granuloma. *J. Immunol.* 112:222–228.
- Meneghin A, Hogaboam CM (2007). Infectious disease, the innate immune response and fibrosis. *J. Clin. Invest.* 117:530-538.
- Mezey E, Liu X, Potter J (2011). The combination of selenium and vitamin E inhibits type I collagen formation in cultured hepatic stellate cells. *Biol. Trace Elem. Res.* 140:82–94.
- Misciagna G, De Michele G, Guerra V, Cisternino AM, Di Leo A, Freudenheim JL (2004). Serum Fructosamine and colorectal adenoma. *Eur. J. Epidemiol.* 19:405-407.
- Mohamed AA, Abo-Amou DE, Shehata MA, El-Ashery NE (2001). Glutathione peroxidase and nitric oxide in patients with chronic liver diseases. *Egypt. J. Schistosomiasis Infect Endem. Dis.* 23:27-46.
- Mohamed AM, Mahmoud SS, Farrag AA (2008). Influence of *Sativa* seeds against liver fibrosis and consequence complications in murine schistosomiasis. *Int. J. Biotechnol. Biochem.* 4:325–346.

- Morais CN, Carvalho BM, Melo WG, Melo FL, Lopes EP, Domingues AL, Jucá NT, Martins JR, Diniz GT, Montenegro SM (2010). Correlation of biological serum markers with the degree of hepatic fibrosis and necroinflammatory activity in hepatitis C and schistosomiasis patients. *Mem Inst Oswaldo Cruz Rio de Janeiro*. 105:460-466.
- Moron MS, Depierre JW, Mannervik B (1979). Levels of glutathione, glutathione reductase and glutathione S-transferase activities in rat lung and liver. *Biochim Biophys Acta*. 582:67-78.
- Moshage H, Kok B, Huizenga JR, Jansen PL (1995). Nitrite and nitrate determinations in plasma: a critical evaluation. *Clin Chem*. 41:892-896.
- Parola M, Robino G (2001). Oxidative stress-related molecules and liver fibrosis J. *Hepatology*. 35:297-306.
- Pender SL, Fell JM, Chamow SM, Ashkenazi A, MacDonald TTA (1998). p55 TNF receptor immunoadhesin prevents T-cell-mediated intestinal injury by inhibiting matrix metalloproteinase production. *J. Immunol*. 160:4098-5103.
- Persijn JP, van der Slik W (1976). A new method for the determination of gamma-glutamyltransferase in serum. *J. Clin. Chem. Clin. Biochem*. 14(9):421-427.
- Poli G (2000). Pathogenesis of liver fibrosis: role of oxidative stress. *Mol Aspects Med*. 21:49-98.
- Potter JJ, Tankesley LR, Mezey E (2003). Influence of leptin in the development of hepatic fibrosis produced in mice by *Schistosoma mansoni* infection and by chronic carbon tetrachloride administration. *J. Hepatology*. 38:281-288.
- Retter R (2002). Melatonin reduces oxidative damage and increases survival of mice infected with *Schistosoma mansoni*. *Free Radic Biol. Med*. 32:319-332.
- Ruiz-Larrea MB, Leal AM, Liza M, Lacort M, de Groot H (1994). Antioxidant effects of estradiol and 2-hydroxyestradiol on iron-induced lipid peroxidation of rat liver microsomes. *Steroids* 59:383-388.
- Shen D Z (2008). A target role for mast cell in the prevention and therapy of hepatic fibrosis. *Med. Hypotheses* 70:760-764.
- Silva LM, Oliveira AS, dos-Santos RR, Andrade ZA, Soares MBP (2004). Comparison of immune responses of *Schistosoma mansoni*-infected mice with distinct chronic forms of the disease. *Acta Tropica* 91:189-196.
- Smithers SE, Terry RJ (1965). The infection of laboratory hosts with cercariae of *S. mansoni* and recovery of worms. *J. Parasitol*. 55:695-700.
- Sodhi S, Sharma A, Brar APS, Brar RS (2008). Effect of a tocopherol and selenium on antioxidant status, lipid peroxidation and hepatopathy induced by malathion in chicks. *Pesticide Biochem. Physiol*. 90:82-86.
- Soudani N, Ben Amara I, Sefi M, Boudawara T, Zeghal N (2011). Effects of selenium on chromium (VI)-induced hepatotoxicity in adult rats. *Exp. Toxicol. Pathol. Exp. Toxicol. Pathol*. 63:541-548.
- Souza ALS, Roffe E, Pinho V, Souza DG, Silva AF, Russo RC, Guabiraba R, Pereira CAJ, Carvalho FM, Barsante MM, Oliveira RC, Fraga LAO, Correa DN, Teixeira MM (2005). Potential role of the chemokine macrophage inflammatory protein1 α in human and experimental schistosomiasis. *Infect Immun*. 73:2515-2523.
- Torben W, Hailu A (2007). Serum cytokines of the 20Krad-irradiated *Schistosoma mansoni* cercariae vaccinated, primary and superinfected *Cercopethicus aethiops aethiops*. *Exp. Parasitol*. 115:121-126.
- Tuna B, Yorukoglu K, Unlu M, Mungan MU, Kirkali Z (2006). Association of Mast Cells with Microvessel Density in Renal Cell Carcinomas. *Eur. urol*. 50:530-534.
- Vunta H, Belda BJ, Arner RJ, Reddy CC, Vanden Heuvel JP, Prabhu KS (2008). Selenium attenuates proinflammatory gene expression in macrophages. *Mol. Nutr. Food Res*. 52:1316-1323.
- Wagne H, Wolff P (1977). New natural products and plant drugs with pharmacological, biological or therapeutic activity. Springer-Verlag. Berlin- Heidelberg- New York. p.231.
- Wang X, Ikejima K, Kon K, Arai K, Aoyama T, Okumura K, Abe W, Sato N, Watanabe S (2011). Ursolic acid ameliorates hepatic fibrosis in the rat by specific induction of apoptosis in hepatic stellate cells. *J. Hepatology*. 55:379-387.
- World Health Organization (2012). Scistosomiasis. Fact Sheet No 115; January. Available at <http://www.who.int/mediacentre/factsheets/fs115/en/index.html>.