

Case report

Importance of molecular techniques in diagnosing Williams-Beuren syndrome

Iravathy Goud .K^{1*}, Dayakar.S¹, Babu.S.J¹, Vijaya Lakshmi .K¹, Peter Miny², Friedel Wenzel³, Dharmendra Jain⁴, Vimarsh Raina⁴

¹Molecular Biology and Cytogenetics lab, Apollo Health city, Jubilee Hills, Banjara Hills, Hyderabad-500033.

²Abteilung Medizinische Genetik, Departement Klinisch-Biologische Wissenschaften Universitäts-Kinderspital beider Basel (UKBB) CH-4005.

³Chromosomenlaboratory, The Children's Hospital, Basel, CH-4005.

⁴Immunology and Molecular Biology, Indraprastha Apollo Hospitals, Sarita Vihar, New Delhi-110044

Accepted 22 February, 2015

Williams's syndrome is a complex syndrome characterized by developmental abnormalities, craniofacial dysmorphic features, and cardiac anomalies. Clinical diagnostic criteria are available for WS; the mainstay for diagnosis is detection of the contiguous gene deletion of the Williams-Beuren syndrome critical region (WBSCR) that encompasses the elastin (*ELN*) gene which can be detected using fluorescent in situ hybridization (FISH) or targeted mutation analysis. A two and half year old child was referred to our Molecular Biology and Cytogenetic lab for cytogenetic analysis which revealed normal male karyotype. As the diagnosis could not be confirmed the sample was further tested for WBS critical region - *ELN*-locus in 7q11 by FISH analysis. Loss of *ELN*-locus in 7q11 confirmed the clinical diagnosis of WBS in the child. The parents of the child benefited enormously by learning that the risk of recurrence was < 1% as this microdeletion occurs sporadically (new mutation). The main aim of this study is to emphasize on two aspects: (i) the importance of making use of modern molecular techniques to diagnose such a syndrome and (2) the difficulties faced by the physician to provide appropriate diagnosis and the adequate genetic counseling to such patients due to the lack of such molecular facilities.

Keyword: Williams- Beuren Syndrome, cytogenetics, FISH

CASE REPORT

A two and half year old male child was a product of full term delivery with normal perinatal period and no history of consanguinity. The child had speech delay and feeding difficulties, did not indicate toilet needs, and was drooping. None of the family members were affected with a similar illness and there was no history of suggestive intrauterine infection in the antenatal period.

Physical examination showed mild coarse features of face, macroglossia, broad brow, bitemporal narrowness, short nose, full nasal tip, long philtrum, full lips, wide mouth, small jaw, and prominent earlobes. There was no hepatosplenomegaly. Investigation for TORCH group of infections of the parents and the child showed negative results. MRI of the brain showed normal images.

The family was under social pressure to have another

child, but wanted to have an objective and measurable understanding about the risk of recurrence of the problems in a subsequent pregnancy. The family was referred for a genetic diagnosis and counseling to the Molecular Biology and Cytogenetics lab, Apollo Hospitals, Hyderabad, India.

A detailed work up was planned for objectively investigating the patient for diagnosing the disease. Cytogenetic analysis of the patient was performed at Molecular Biology and Cytogenetics lab, Apollo Hospitals, Hyderabad. After taking an informed consent from the parents, peripheral blood sample was collected from the child (proband) in a heparinized vacutainers (green top) and processed for cytogenetic analysis, lymphocyte stimulated cultures were set up, methodology after Moorehead et al (1960). Giemsa banding (GTG banding) was performed, Seabright (1970). At least 30 metaphases were scored under light transmission microscope and Leica karyotyping soft ware was used for

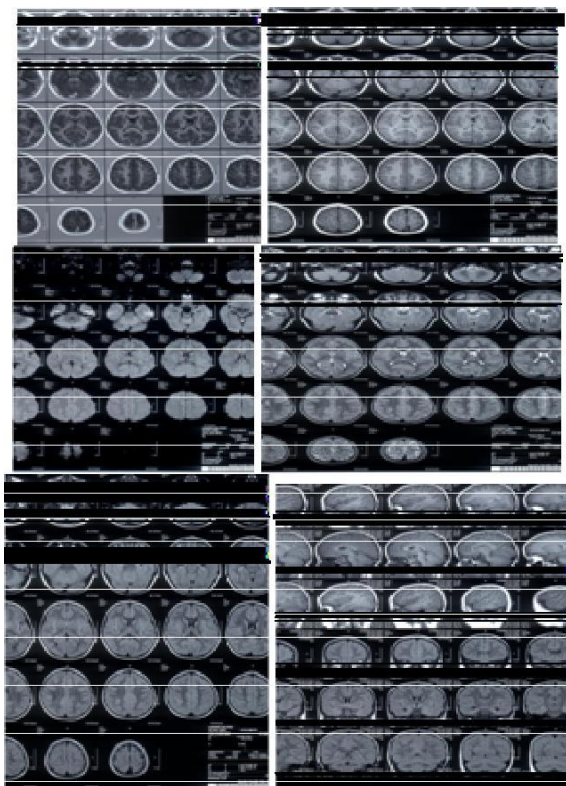


Figure 1. MRI Images of the Brain (The cerebral parenchyma shows normal configuration pattern of gray and white matter and normal signal intensities, with no evidence of any obvious focal or diffuse pathology)

cytogenetic analysis. Three metaphases were karyotyped according to International System for Human Cytogenetic Nomenclature (ISCN) criteria, Mitelman (2005). Usually the total chromosome count was determined in 30 cells, but if mosaicism was suspected then 50 or more cell counts were undertaken, Kingston (1994). As the cytogenetic analysis showed normal male karyotype (46, XY) for child without any numerical and structural anomalies, peripheral blood sampling was repeated for the child and sent to Medizinische Genetik, Universitäts-Kinderspital beider Basel (UKBB) and Department Klinisch- Biologische Wissenschaften (DKBW), for FISH analysis for the ELN-locus in 7q11. The peripheral blood sample of the patient was processed for FISH-analysis, using a 72 h-blood culture for preparation of metaphase spreads according to standard cytogenetics techniques. FISH was performed using a commercially available WBS critical region-probe (Kreatech Diagnostics, Amsterdam, Netherlands, KBI-40111) which covers the ELN-region in 7q11. According to the manufacturer's protocol a co-denaturation (75°C, 10 minutes) was done, followed by over-night hybridisation at 37°C.

For post-hybridisation washing, a washing solution (0.4x SSC with 0.3% NP-40 (Nonidet P-40)) was used for

2 minutes at 72°C, followed by a second washing step in 2x SSC with 0.1% NP-40 at room temperature for 1 minute. Afterwards the slide was air-dried for 20 minutes on a 37°C heating plate and mounted in DAPI II (4'-6'-diamidino-2-feniloide) counterstain (Abbott/Vysis Inc., Downers Grove, IL, USA). Microscopy was carried out using an Axioscope fluorescence microscope (Carl Zeiss AG, Feldbach, Germany) equipped with single bandpass filters for SpectrumGreen, Spectrum Orange and DAPI. For digital imaging the FISH-View-Software (ASI, Edingen-Neckarhausen, Germany) was used. Totally 10 metaphases were analyzed for deletion of 7q11 (red signals) and a control probe at 7q22 (green signals).

RESULTS

The MRI pictures showed normal images. Axial -T1, T2, FLAIR, DW; sagittal- T1 and coronal -flair sections of the brain were studied. The cerebral parenchyma shows normal configuration pattern of gray and white matter and normal signal intensities, with no evidence of any obvious focal or diffuse pathology. Myelinisation was appropriate for patient's age. Basal ganglia, thalami, midbrain, brainstem and both cerebellar hemispheres showed normal morphology and MR signals. The ventricular system presented normal configuration. There was no shift of midline. The subarachnoid cisterns and cortical sulci showed normal configuration. Both orbits and the soft tissues of the face appeared normal (Figure 1).

The Cytogenetic analysis with GTG banding showed normal male karyotype (46, XY) without any structural and numerical anomalies (Figure 2).

The FISH analysis – using a probe set comprising the ELN-locus from the WBS critical region at 7q11 (red signal) and a control probe at 7q22 (green signal) – showed one red signal on one of the chromosome 7, whereas on the second chromosome 7 the red signal was missing (both chromosomes 7 identified by the control probe). This signal pattern clearly confirms the deletion of the WBS critical region on 7q11 (Figure 3).

DISCUSSION

Williams Beuren syndrome was first noted with dysmorphic facial features which resembled elves of legend, and from then, the term "Williams elfin facies syndrome" was used. After the reports of Williams et al (1961) and Beuren et al (1962), the condition was called Williams syndrome in the United States and Williams-Beuren syndrome in Europe. Horowitz et al (2002) reported the annual incidence of WBS as one in 20,000-50,000 live births.

It is a multi- system disorder that requires ongoing management by a primary care physician familiar with the

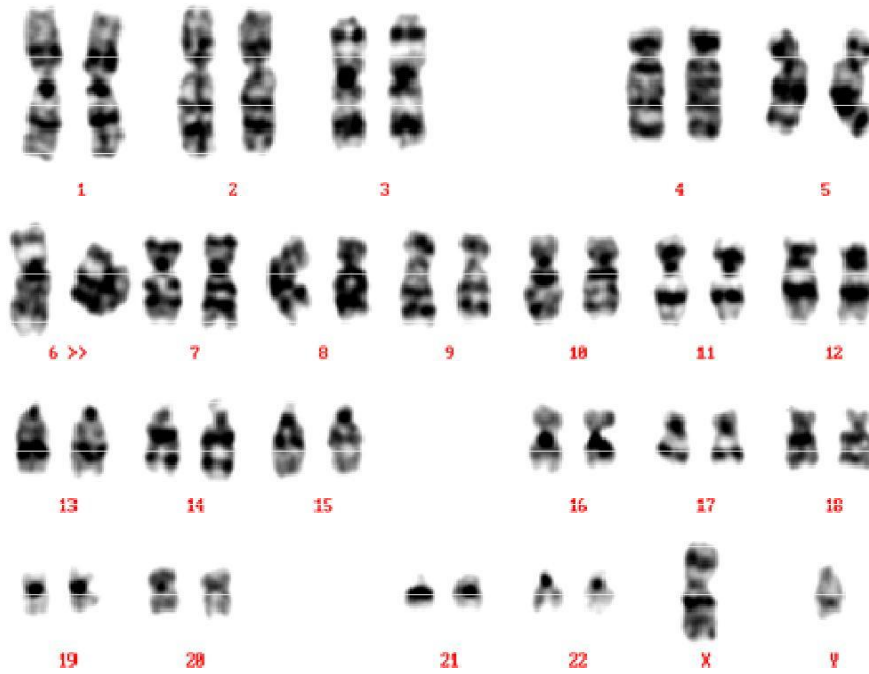


Figure 2. Normal male karyotype of the patient (46, XY)

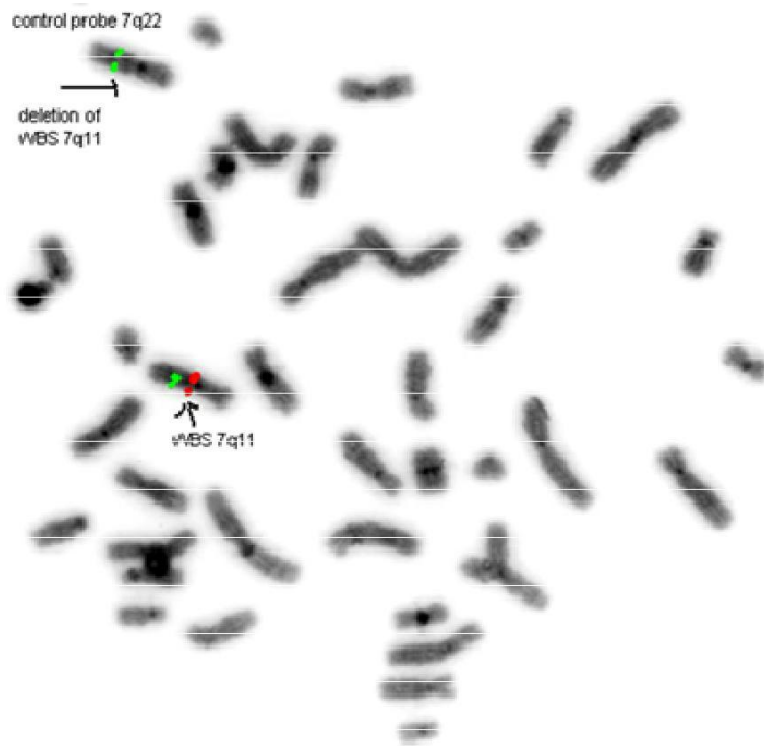


Figure 3. Metaphase showing two signals for the control probe at 7q22 (Green signal) and only one signal for the WBS locus- 7q11 (red signal) indicating deletion of 7q11 on one of chromosome number 7

natural history and common medical problems associated with the condition. Some abnormalities are unique to WBS, such as the elastin arteriopathy that often manifests as supraaortic stenosis and hypertension. Still other features, such as diverticulosis, are seen in the general population but tend to present earlier in WBS. Lifelong monitoring of the cardiovascular and endocrine systems is essential to the clinical management of individuals with Williams-Beuren syndrome. Pober et al (2007) reported that constipation should be aggressively managed, and symptoms of abdominal pain should promptly be evaluated for diverticulosis/diverticulitis. Similar symptoms were noted in the present study.

Due the lack of availability of molecular facilities in many underdeveloped and developing countries there are difficulties faced by the physicians to diagnose this syndrome. And also as WBS is still not understood completely in the field of the phenotype and molecular genetics, it is necessary to use at least two different techniques to diagnose disease accurately. As reported by Punkaj Gupta et al (2010) sudden death is a very common complication associated with anesthesia, surgery, and procedures in this population. There is an urgent need to use molecular tests to confirm the diagnosis and understand the risk-benefit ratio and also the potential risks involved.

The other investigations available to diagnose WBS like physical and neurologic examination, cardiology and urinary system evaluation, ultrasound examination of the bladder and kidneys, thyroid function tests, ophthalmologic and baseline audiologic evaluation, assessment of behavior including attention, anxiety, adaptive skills, neuroimaging which demonstrates isolated hypo activation in the parietal portion of the dorsal stream in the visual processing pathway. However, in the present study the MRI of brain and other above mentioned investigations could not diagnose WBS as they were normal. Hence, further molecular investigations like FISH was carried out. FISH is diagnostic technique often used in diagnosing WBS. WBS locus (7q11) on human chromosome is flanked by complex chromosome-specific low-copy repeats that mediate recurrent genomic rearrangements of the region. Common genomic rearrangements arise through unequal meiotic recombination and result in complex but distinct behavioral and cognitive phenotypes. Deletion of 7q11 results in WBS, which is characterized by mild to moderate intellectual disability or learning difficulties, with relative cognitive strengths in verbal short-term memory and in language and extreme weakness in visuospatial construction, as well as anxiety, attention-deficit hyperactivity disorder and overfriendliness as reported by Lucy et al (2007). Similar symptoms were seen in the present study and also reported earlier by many researchers such as Antonell et al, 2006.

Apart from FISH, Real-time quantitative PCR could also be used to determine the dosage (copy number) of three genes within the WBSCR: ELN (elastin gene), LIMK1, and GTF2I in diagnosis of WBS along with the battery of other investigations, Somerville et al (2002). Genetic counseling for Williams's syndrome is also very important as it is transmitted in an autosomal dominant manner. Most cases are de novo occurrences, but occasionally, parent to child transmission is observed. Prenatal testing is clinically available, but is rarely used because most cases occur in a single family member only and no prenatal indicators exist for low-risk pregnancies. In the present study with the precise analysis of breakpoints with deletion of 7q11 and a good phenotypic characterization helped us in diagnosing the patient with WB. The treatment of the patient is also considered the child has been given speech therapy and specific counseling has been given to the parents. As the parents were clinically normal a very rare familial occurrence was excluded. Since parental germ line mosaicism is probably also very rare, the recurrence risk was also found to be low (< 1%). By looking at all the aspects it was concluded that it could have been a new mutation formed sporadically. Considering the objective evidence of low risk of recurrence of this mutation in a subsequent conceptus, the parents made a conscious decision to try to have another child. Hence, it is recommended that the modern tools of molecular diagnostics would help clinicians to help the prospective anxious parents (who have mentally challenged children) plan their families in a better way.

Conclusions

In cases such as the present case, where a family has significant emotional and social issues to grapple with the conflict as to whether to go for another pregnancy or not, molecular diagnosis can answer if not all but a significant number of queries of the anxious parents. Given these concerns, a thorough explanation of the risk-benefit ratio should be considered whenever diagnostic tests are considered, in patients with WBS, along with a thorough discussion with parents regarding the potential risks involved.

ACKNOWLEDGEMENTS

The authors acknowledge the parents of the child for accepting to give the consent and the Medizinische Genetik, Universitäts-Kinderspital beider Basel (UKBB) and Department Klinisch-Biologische Wissenschaften (DKBW) for accepting to perform the FISH test and the management of Apollo Hospitals for their support.

REFERENCES

- Antonell A, Del Campo M, Flores R, Campuzano V, Perez-Jurado LA (2006). Williams syndrome: its clinical aspects and molecular bases. *Rev Neurol.* 1:S69-75.
- Beuren AJ, Apitz J, Harmjan D (1962). Supravalvular aortic stenosis in association with mental retardation and a certain facial appearance. *Circulation.* 26: 1235-1240.
- Horowitz PE, Akhtar S, Wulff JA, Fadley FA, Halees ZA (2002). Coronary artery disease and anesthesia-related death in children with Williams syndrome. *J Cardiothorac Vasc Anesth.* 16: 739-41.
- Kingston MH (1994). Chromosomal analysis. In: Kingston MH, ed. *ABC of clinical genetics.* London, BMJ Publishing Group. pp 21-25.
- Lucy R, Osborne B, Carolyn M (2007). Rearrangements of the Williams-Beuren syndrome locus: molecular basis and implications for speech and language development. *Expert Reviews in Molecular Medicine,* Cambridge University Press. 9:15:1-16.
- Mitelman F (2005). *ISCN. An International System for Human Cytogenetic Nomenclature.* Basel Karger. pp 1-115.
- Moorehead PS, Nowell PC, Mellman WJ, Battips DM, Hungerford DA (1960). Chromosome preparation of leukocytes cultured from human peripheral blood. *Exp. cell Res.* 20:613-616.
- Pober BR, Morris CA, (2007). Diagnosis and management of medical problems in adults with Williams-Beuren syndrome. *Am. J. Med. Genet. C Semin Med Genet.* 145C(3):280-90.
- Punkaj G, Joseph DT, Sunali G, Martin DM, Elliot M, Natan N, Michael M, Vipin M (2010). Sudden cardiac death under anesthesia in pediatric patient with Williams syndrome: A case report and review of literature. *Annals of cardiac anesthesia.* 13: 44-48.
- Seabright M (1971). A rapid banding technique for human chromosomes. *Lancet.* 2:971-972.
- Somerville MJ, Tomaszewski R, Hicks M, Sprysak KA, Elyas BG, Ng AY, Haase SM, Vicens-Wyhony LM (2002). PCR dosage-based testing for genes spanning the Williams-Beuren syndrome critical region. *Am. J. Hum. Genet* 71: 375.
- Williams JC, Barratt-Boyes BG, Lowe JB (1961). Supravalvular aortic stenosis. *Circulation.* 24:1311-1318