



Full Length Research Paper

Histological effect of aqueous extract of *Anacardium occidentale* (Cashew) stem bark on adult Wistar rat testis

OYESOMI, Tajuden Oyesina* and AJAO Moyosore Salihu

Department of Anatomy, Faculty of Basic Medical Sciences, College of Health Sciences, University of Ilorin, Ilorin, Kwara State, Nigeria.

Accepted 24 October, 2018

In medical practice, *Anacardium occidentale* stem bark is used for various ailment treatments. Possible histological effects of aqueous extract of *A. occidentale* stem bark administration was studied on adult Wistar rat testes. The rats (n=24), weighing 164 to 210 g were randomly assigned into three treatments (n=18) and control (n=6) groups. The rats in the treated groups II, III, IV received 20, 40 and 60 mg/kg aqueous extract of *A. occidentale* stem bark orally via orogastric tube for twenty-one days, while the control group I received only equal volume of phosphate buffer saline (PBS). The rats were fed with growers' mash and given water liberally. Cage side examination was done daily to observe overt signs of toxicity (salivation, lacrimation, yellowing of fur e.t.c). Twenty-four hours after the expiration of the extract administration, rats were sacrificed; the testes were excised and fixed in Bouin's fluid for routine hematoxylin and eosin histological study. The histological findings of testes sections indicated that there were no cyto-architectural distortions and no evidence of apoptotic bodies in the treated groups as compared to the control group. These findings suggest that aqueous extract of *A. occidentale* does not have effect on the adult Wistar rat testis.

Keywords: *Anacardium occidentale*, cyto-architectural, non-toxic, adult male Wistar rat.

INTRODUCTION

Plants and animals are interrelated in their environment. Plants serve as sources of food and medicinal herbs for Man and other animals in their environment. Thousands of years ago, Man has depended on plants in order to provide solutions to the myriad of health problems plaguing Him (Oliver, 1960).

In the last 20 years, the interest in medicinal plants has increased together with the number of investigations into their biological effects on human beings and animals (Veiga et al., 2005). Although, poisonous plants are ubiquitous, herbal medicine is used by up to 80% of the population in the developing countries (Jaouad et al., 2004).

Medicinal plants are believed to be an important source of new chemical substances with potential therapeutic effects (Farnsworth, 1989; Eisner, 1990).

The cashew (*Anacardium occidentale*) is a tree in the family of the flowering plant Anacardiaceae. The family contains 73 genera and about 600 species (Correa, 1978). *Anacardium* contains 8 species, native to tropical America, of which the cashew is by far the most important economically (Morton, 1987). It is a multipurpose tree of the Amazon that grows up to 15 m high (Morton, 1987; de Souza et al., 1992).

Cashew gum is used in pharmaceuticals and as substitute for gum Arabic (Patro and Behera, 1979). Extracts from roots, stems and fruits of *A. occidentale* L., (Sokeng et al., 2001) have been used by the Cameroonian and other countries' folk medicine. In the traditional Nigerian and Brazilian pharmacopoeia, stem-bark of *A. occidentale* L. is known for its anti-inflammatory effects (Mota et al., 1985; Chen and Chung,

*Corresponding author. E-mail: drstoyesomi@yahoo.com or oyesina1@gmail.com. Tel: +2347032986771, +2347054367216 or +2348026622841.

2000; Ojewole, 2004). The leaves and/or the bark is also used in Brazil for eczema, psoriasis, scrofula, dyspepsia, genital problems, and venereal diseases, as well as for impotence, bronchitis, cough, intestinal colic, leishmaniasis, and syphilis-related skin disorders (Franca et al., 1993). A strong antioxidant capacity was also observed against hepatocarcinogenesis induced by aflatoxin B1 in Wistar mice (Premalatha and Sachdanandam, 1999).

Preclinical studies realized with metabolites isolated from the bark of this tree species demonstrated antipyretic action for anacardic acid (Eichbaum, 1988). Polasa and Rukmini (1987) realized mutagenic tests with vegetable oil derived from cashew nut, which presented mutagenicity with or without the activation of the S9 fraction in *Salmonella typhimurium*. However, MeloCavalcante et al. (2003) and Venkatachalam and Sathe (2006) demonstrated that tannic acid, a compound present in the cashew, presented an antimutagenic effect on the *Salmonella typhimurium* TA 98 lineage. The bark and leaves of cashew are a rich source of tannins, a group of plant chemicals with documented biological activity (Laurens, 1999). These tannins, in a 1999 rat study, demonstrated anti-inflammatory and astringent effects, which may be why cashew is effective in treating diarrhoea (Laurens, 1999). Several clinical studies have shown that these chemicals curb the darkening effect of aging by inhibiting tyrosinase activity, and that they are toxic to certain cancer cells (Kubo et al., 1994).

Ofusori et al. (2008) reported that *A. occidentale* do not have a toxic effect on the brain and kidney of Swiss albino mice. Tedong et al. (2007) reported that extract amount less than 6 g/kg is not toxic for mice and high doses may have side effects.

There are no reports in the literature on the effect of aqueous extract of *A. occidentale* (cashew) stem bark on the testis of adult Wistar rats. The present study therefore was undertaken to evaluate the effect of this plant extract on the testis of the Wistar rats.

MATERIALS AND METHODS

The study was approved by the Research Ethical Committee of the Faculty of Basic Medical Sciences, College of Health Sciences University of Ilorin, Ilorin, Nigeria.

Plant material

Samples of *A. occidentale* were collected within Obafemi Awolowo University Senior Staff Quarters (Road 18), Ile-Ife in Osun State. Botanical identification of the plant was done at the herbarium section in the Department of Botany University of Ilorin, Ilorin.

Extract preparation

Fresh stem bark of *A. occidentale* was air dried at room temperature and pulverized with pestle and mortar. 120 g of the

coarse powder was macerated with 1000 mls distilled water and the mixture was left for 48 h, mixture was filtered and filtrate was concentrated in a vacuum at 20°C (Ofusori et al., 2008) to yield the dark brown extract (paste). The extract weighed 21 g after the vacuum concentration using Gallenkamp (FA2104A, England). The solid extract was stored in a refrigerator until use (-20°C).

Experimental animals

Twenty-four adult male Wistar rats purchased from the animal house of the Department of Biochemistry, University of Ilorin with their weight ranging between 164 to 210 g rats were bred in the animal house of the Department of Anatomy, University of Ilorin. The rats were housed and maintained under standard conditions (12 h light/dark cycles). Food (pellet from Bendel Feeds, Yoruba Road, Ilorin) and distilled water was given *ad libitum*. The animals were care for in accordance with the recommendations provided in the "Guide for the Care and Use of Laboratory Animals" prepared by the National Academy of Sciences (NIH, 1985).

Grouping of animals

The animals were randomly divided into four groups of six animals each, (a control (group I), and 3 experimental groups II, III, IV). Body weights of the animals were obtained using a weighing scale (Gallenkamp FA2104A, England).

Administration of extract

Extract was administered orally to the rats by carefully inserting the syringe with the needle affix into the oral cavity of the rats. Group I serves as the control group and received phosphate buffered saline while Group II, III, IV received 20, 40 and 60 mg/kg extract, respectively for 21 days. Cage side examination were performed daily to detect overt signs of toxicity (salivation, lacrimation, chewing jaw movements, ptosis, squinting, writhing, convulsion, tremors, yellowing of fur, loss of hair, stress, erection of fur, vocalization and exophthalmia, behavioural abnormalities and dead rats) (Ratnasooriya et al., 2003).

After 24 h of the last administration, the animals were sacrificed by cervical dislocation and the testes was excised and fixed in Bouin's fluid for histological studies.

Histological techniques

Paraffin tissue processing

Excised testes were fixed by immersion for the routine histological studies using Bouin's fluid for 18 h, dehydrated through series of graded alcohol, cleared in xylene, infiltrated and embedded in molten paraffin wax. Tissue blocks were sectioned at 6µm thickness deparaffinized and stained with Heamatoxylin and Eosin. The sections were examined with the light microscope and photomicrographs of the sections were taken for further analysis.

RESULTS

Physical and behavioural observation

From observation made, there was no difference in behavioural changes noticed between the control group

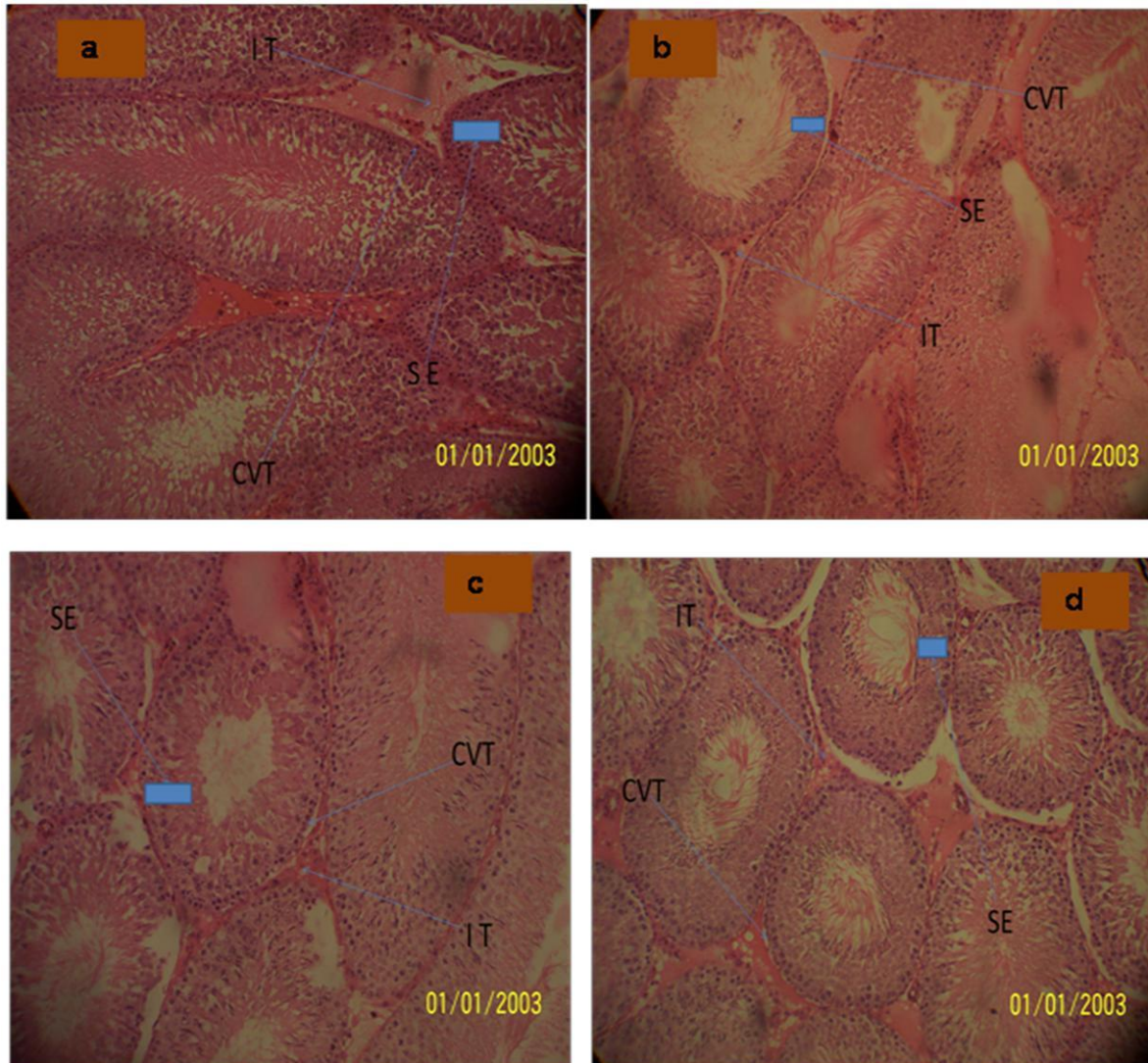


Figure 1. Photomicrographs of the testis at 21 day of treatment (a) Control group I (b) Group II treated (20ml/kg bodyweight) (c) Group III treated (40ml/kg bodyweight) and (d) Group IV treated (60ml/kg bodyweight) showing SE- Seminiferous epithelium, IT – Interstitial Tissue, CVT – Convoluted tubules (x1200).

and experimental groups. There was no mortality, stress or abnormal behavioural changes observed within the treated groups throughout the administration periods. Overt signs of toxicity such as lacrimation, squinting and, exophthalmia etc, were not expressed by the rats throughout period of study.

Histological Observations

The histological observation of the testes showed no distortion in cell architectures of the treated groups. The seminiferous epithelium (SE), interstitial tissue (IT) and CVT – convoluted tubules – CVT of the treated groups showed no difference from that of the control (Figure 1a to d).

DISCUSSION

Effects of *A. occidentale* stem bark on the testis were investigated to highlight the possible histological implications that could result following its consumption. The study reveals that aqueous extract of cashew stem bark has no toxic effect on the testis cyto-architecture. The pharmacological mechanism behind this result may be traced to some phytochemical contents of *A. occidentale*. The stem bark of cashew is adopted in Africa as antimalaria therapy. Ngadjui et al. (2002) noted in his work on „antimalarial agents from some Cameroonian plants' that, abiatane diterpenoids, quinines, triterpenoids and flavonoids are the principal phytochemical contents of some of the plants screened. Although some of these phytochemicals may not have

been successfully isolated in *A. occidentale* as literature is scanty in this area, it is believed that some of its phytochemicals may be synonymous to that found in some other plants such as *Croton zambesicus* also used traditionally in Nigeria as antimalaria therapy. Flavonoids, alkaloids and tannins have been investigated by Abo et al. (1999) and Nweze et al. (2004) to possess antimicrobial effects in various studies using plant extracts. However, more research is required to determine the role of tannins and other phytochemicals in *A. occidentale*.

However, the toxicity of *A. occidentale* L. has not been extensively studied. Paris et al. (1977) observed no toxic effects in mice treated with aqueous extracts of *A. occidentale* at doses of up to 2 g/kg by oral route while the same extract taken by *i.p.* route showed that LD₅₀ is 0.250 g/kg.

In a study, acute, 30-day sub acute toxicity and genotoxicity assays were carried out. The crude extract did not produce toxic symptoms in rats in doses up to 2000 mg/kg (Koran et al., 2007). Tedong et al. (2007) reported that extract amount less than 6 g/kg is not toxic for mice and high doses may have side effects.

Malini and Vanithakumari (1990) indicated that chronic administration of β -sitosterol (lipids isolated from *A. occidentale* leaf extract) subcutaneously to rats for 60 days was well tolerated and there was no clear evidence of any lesions either in the liver or in the kidney. Although the fruits of *A. occidentale* are commonly eaten, leaves and barks have been shown to display a wide spectrum of biological and pharmacological activities, which provide experimental support for empiric ethnopharmacological use of this plant in folk medicine. *Anacardium* has been reported to have anti-inflammatory actions (Mota et al., 1985; Ojewole, 2004), antimicrobial (Laurens, 1999), hypoglycaemic and antidiabetic (Kamtchouing et al., 1998; Ojewole, 2004; Tedong, 2006) and molluscicide (Mendes et al., 1990) activity. The folkloric use of *A. occidentale* may be validated by this study since the therapeutic dose often used is higher to the dose exhibiting non-toxicity in the study.

In conclusion, the functions of the testis do not influenced from cashew stem bark juice doses. We recommend that the study may be the baseline for *A. occidentale* investigations about antimicrobial and anti-inflammatory effects on experimental testis studies like orchitis.

REFERENCES

- Abo KA, Ogunleye VO, Ashidi JS (1999). Antimicrobial potential of *Spondias mombin*, *Croton zambesicus* and *Zygotritonia crocea*. *Phytother. Res.*, 13(6): 494-497.
- Chen S, Chung K (2000). Mutagenicity and Antimutagenicity Studies of Tannic acid and its related compounds. *Food Chem. Toxic.*, 38: 1-5.
- Correa MP (1978). *Dicionário de plantas úteis do Brasil*. Ministério da Agricultura, IBDF: Rio de Janeiro, p. 55 (in Portuguese).
- De Souza CP, Mendes NM, Janotti-Passos LK, Pereira JP (1992). The used of the shell of cashew nut, *Anacardium occidentale*, as an alternative molluscicide. *Rev. Inst. Med. Trop. So Paulo.*, 34(5): 459-466.
- Eichbaum FW (1988). Biological properties of anacardic acid (O-pentadecadienyl-salicylic acid) and related compounds. *Memórias do Instituto Butantã.*, 19: 119-133.
- Eisner T (1990). Chemical Prospecting: A Call for Action. In: Borman, F.E and S.R. Kellert (Eds), *Ecology, Economic and Ethics: The Broken Circles*. Yale University Press, New Haven, CT.
- Farnsworth NR (1989). Screening Plants for New Medicine. In: Wilson, E.O (Ed.), *Biodiversity*. Part II. National Academy Press, Washington, pp. 88-97.
- Franca F, Cuba CA, Moreira EA, Miguel O, Almeida M, das Virgens ML, Marsden PD (1993). An evaluation of the Effect of a bark extracts from the cashew (*Anacardium occidentale* L.) on infection by *Leishmania (Viannia) brasiliensis* [in Portuguese]. *Revista Sociedade Brasileira de Medicina Trop.*, 26: 151-155
- Jaouad EH, Israilli ZH, Lyoussi B (2004). Acute toxicity and chronic toxicological studies of *Ajuga iva* in experimental animals. *J. Ethnopharma.*, 91: 43-50.
- Kamtchouing P, Sokeng DS, Moundipa PF, Watcho P, Jatsa BJ, Lontsi D (1998) Protective role of *A. occidentale* extract against streptozotocin-induced diabetes in rats. *J. Ethnopharma.*, 65: 95-99.
- Koran NA, Marianne EB, Lincopan N, Varela SD, Varanda EA (2007). Acute, Subacute toxicity, genotoxic effect of a hydroethanolic extract of the cashew (*Anacardium Occidentale* L.) *J. Ethnopharm.*, 110(1): 30-38.
- Kubo J (1994). Tyrosinase inhibitors from *Anacardium occidentale* fruits. *J. Nat. Prod.*, 57(4): 545-551.
- Laurens AC (1999). Screening of some medicinal plants for antimicrobial activity. *J. Ethnopharma.*, 67(2): 225-228.
- Malini T, Vanithakoumari G (1990). Rat toxicity studies with β -sitosterol. *J. Ethnopharm.*, 28: 221-234.
- MeloCavalcante AA, Rubensam G, Picada JN, Gomes da Silva E, Fonseca Moreira, JC, Henriques JA (2003). Mutagenicity, antioxidant potential, and antimutagenic activity against hydrogen peroxide of cashew (*Anacardium occidentale*) apple juice and cajui. *Environ. Mol. Mutagen.*, 41: 360-369.
- Mendes NM, de Oliveira AB, Guimareas JE, Pereira JP, Katz N (1990). Molluscicide activity of mixture of 6-n-alkyl salicylic acids (anacardic acid) and 2 of its complexes with copper (II) and lead (II) *Rev Soc Bras Med Trop.*, 23(3): 217-224.
- Morton JF (1987). *Fruits of Warm Climates*. Flair Books, Florida, ISBN: 0-9610184-1-0.
- Mota MLR, Thomas G, Barbosa Filho JM (1985). Anti-inflammatory actions of tannins isolated from the bark of *Anacardium occidentale* L. *J. Ethnopharm.*, 13(3): 289-300.
- National Institutes of Health (1985). *Guide for the Care and Use of Laboratory Animals: DHEW Publication (NIH)*, revised. Office of Science and Health Reports, DRR/NIH, Bethesda, USA.
- Ngadjui BT, Abegaz BM, Keumedjo F, Folefoc GN, Kapche GWF (2002). Diterpenoids from the stem bark of *Croton zambesicus*. *J. Phytochem.*, 60: 345-349.
- Nweze EI, Okafor JI, Njoku O (2004). Antimicrobial Activities of Methanolic Extract of *Trume guineensis* (schumm and thorn) and *Morinda lucinda* Benth used in Nigerian Herbal Medicinal Practice. *J. Biol. Res. Biotechnol.*, 2(1): 34-46.
- Ofusori. D, Enaibe B, Adelakun A, Adesanya O, Ude R, Olyemi K, Okwuonu C and Apantaku O (2008). Microstructural Study of the Effect of ethanolic extract of Cashew stem bark *Anacardium occidentale* on the Brain and Kidney of Swiss albino mice. *Int. J. Alter. Med.*, 5(2).
- Ojewole JA (2004). Potentiation of the anti-inflammatory effect of *Anacardium occidentale* (Linn) stem-bark extract by grapefruit juice. *Methods Find Exp J. Clin Pharmacol.*, 26: 183-188.
- Oliver B (1960). *Medicinal plants in Nigeria*. Ibadan College of Arts and Sciences and Technology, Ibadan, P. 358.
- Paris R, Phat M, Giono-Barber, Linhard J, Laureus J (1977) Recherche chimique et pharmacologique sur les feuilles d'*Anacardium occidentale* L. (*Anacardiacees*) *Bull soc Med Afr. Noire*, 22(3): 275-281.
- Patro C, Behera RN (1979). Cashew helps to fix sand dunes in Orissa. *Indian Farming*, 28(12): 31-32.

- Polasa K, Rukmini B (1987). Mutagenicity tests of cashewnut shell liquid, rice-bran oil and other vegetable oils using the *Salmonella typhimurium*/microsome system. *Food Chem. Toxicol.*, 25: 763-766.
- Premalatha B, Sachdanandam P (1999). *Semecarpus anacardium* L. nut extract administration induces the *in vivo* antioxidant defence system in aflatoxin B1 mediated hepatocellular carcinoma. *J. Ethnopharm.*, 66: 131-139.
- Ratnasooriya WD, Jayakody JRAC, Premakumara GAS (2003). Adverse pregnancy outcome in rats following exposure to a Salacias reticulate (Celastraceae) root extract. *Braz. J. Med. Biol. Res.*, 36: 931-935.
- Sokeng DS, Kamtchouing P, Watcho P, Jatsa HB, Moundipa PF, Ngounou FN, Lontsi D, Bopelet M (2001). Hypoglycemic activity of *Anacardium occidentale* L. Aqueous extract in Normal and streptozotocin-induced diabetic rats. *Diab Res.*, 36: 001-009.
- Tedong L, Dimo T, Dzeufiet PDD, Asongalem AE, Sokeng DS, Callard P, Flejou JF, Kamtchouing P (2006). Antihyperglycemic and renal protective activities of *Anacardium occidentale* (Anacardiaceae) leaves in streptozotocin induced diabetic rats. *Afr. J. Trad. CAM.*, 3(1): 23-35.
- Tedong L, Dzeufiet PDD, Dimo T, Asongalem EA, Soheng SD, Flejou JF, Callard P, Kamtchouing P (2007). Acute and subchronic Toxicity of *Anacardium occidentale* Linn. (*Anacardiaceae*) Leaves Hexane Extract in Mice. *Afr. J. Trad. Compl. Altern. Med.*, 4(2): 140-147.
- Veiga Jr. VF, Pinto AC, Maciel MAM (2005). Plantas Mediciniais: Cura Segura? *Química Nova*, 28: 519-528.
- Venkatachalam M, Sathe SK (2006). Chemical composition of selected edible nut seeds. *J. Agric Chem.*, 54: 4705-4714.