

Full Length Research Paper

Expanded use of the dermatoscope and otoscope in the physician's office

Sody A. Naimer^{1*} and Jacob Urkin²

¹Department of Family Medicine, Siaal Family Medicine and Primary Care Research Center, Faculty of Health Sciences, Ben-Gurion University of the Negev, Beer-Sheva, Israel.

²Division of Health in the Community, Faculty of Health Sciences, Ben-Gurion University of the Negev, Beer-Sheva, Israel.

Accepted 8 September, 2013

The basis of two commonly used utensils in family practice is the compilation of a magnifying component with a light source. The otoscope is designed to illuminate and examine the depth of a narrow cavity, while the dermatoscope is intended for examining the superficial skin surface. This paper provides an overview of ancillary application of these tools for additional clinical indications. The present article describes novel methods of instrument assisted examination helping to bring about a faster, more accurate diagnostics for clinical conditions proven difficult to recognize. Photographic depiction of classic examples is presented. A review of professional literature is quoted if existent. In clinical instances where the chosen instrument was utilized for examination, it consistently conferred greater security of detecting pathology. The diagnostic process was facilitated with insignificant time consumption. The authors recommend the busy physician incorporation of readily available tools for a wider range of applications, whenever superior visualization is assumed beneficial. Although most of the current available knowledge on this topic is either non-existent or based on single observations and small case studies rather than controlled trials, an increasing interest in this field is mounting and we expect it to gain greater popularity.

Key words: Dermatoscopy, otoscopy, illumination, magnification, cutaneous lesions, retained sutures, presurgical assessment, foreign body.

INTRODUCTION

The otoscope commonly used for otolaryngologic conditions and the dermatoscope intended for improving the accuracy of diagnosing pigmented lesions of the skin are two very similar utensils. The basis of each is the compilation of a magnifying component with a light source. The former allows direct vision through a speculum that serves as a guide, while the latter, of greater

magnification capacity, is used via close inspection or actual adherence to the chosen cutaneous or mucosal surface. While the otoscope is designed to illuminate and examine the depth of a narrow cavity, in contrast, the dermatoscope is intended for examination of the superficial surface area of the skin. Beyond their primary role as examination tools for detecting pathology in their respective

*Corresponding author. E-mail: sodyna@clalit.org.il. Tel: 972-8-6477433. Fax: 972-8-6477623

fields of medicine, they can provide a wider range of applications for the busy general practitioner.

Background

The otoscope is one of the medical instruments most frequently used by primary care physicians. Although the aural and nasal specula were described by Guy de Montpellier in France in 1363, prototypes of the modern otoscope were developed in France and Germany only about 500 years later (Kravetz, 2002; Feldmann, 1996). The otoscope has not really changed since its development in the 19th century. The modern otoscope consists of a magnifying glass on the eyepiece, a cone shaped speculum at the end of a tube and a light source that does not obliterate vision. The magnification of the otoscope eyepiece reaches the order of between two to five times the true object.

Dermoscopy (also known as epiluminescence microscopy, dermatoscopy, and amplified surface microscopy) (Figure 1) is an *in vivo* method that has been reported to be a useful tool for the early recognition of malignant melanoma. Skin surface microscopy started in 1663 with Kolhaus who investigated the small vessels in the nailfold with the help of a microscope (Gilje et al., 1958). In 1878, Abbe described the use of immersion oil in light microscopy and this principle was transferred to skin surface microscopy by the German dermatologist Unna, in 1893 (Saphier, 1920). He introduced the term "diascopy" and described the use of immersion oil and a glass spatula for the interpretation of lichen planus and for the evaluation of the infiltrate in lupus erythematosus. The term "dermatoscopy" was introduced in 1920 by the German dermatologist Johann Saphier who published a series of communications using a new diagnostic tool resembling a binocular microscope with a built-in light source for the examination of the skin (Campos-doCarmo and Ramos-e-Silve, 2008). Skin surface microscopy was further developed in the United States by Goldman in the 1950s. He published a series of articles on new devices that he called "Dermoscopy" (Goldman, 1951).

In 1971, Rona MacKie (Campos-doCarmo and Ramos-e-Silve, 2008) clearly identified for the first time the advantage of surface microscopy for the improvement of preoperative diagnosis of pigmented skin lesions and for the differential diagnosis of benign versus malignant lesions. Today, dermoscopy has become a routine technique and some consider naked eye specialist examination of pigmented lesions devoid of dermoscopy as negligent medical care.

Dermoscopy can be performed with very simple, inexpensive equipment (Braun et al., 1999; Bahmer and Rohrer, 1986). Specially designed handheld devices with 10 to 20 times magnification are commercially available (Dermatoscope [Heine AG]; DermoGenius Basic



Figure 1. Recently developed product: "Dermlite III hybrid" allowing illumination in cross-polarized or non-polarized immersion fluid dermoscopy with optional cellular telephone photography (3Gen LLC).

[Rodenstock Präzisionsoptik]; Episcopes [Welch-Allyn]; DermLite [3Gen, LLC]). The advantage of the dermatoscope is that it permits the direct interface scrutiny of the cutaneous surface directly under the contact glass of the instrument. With the turn of the century, a Californian invented polarized dermoscopy which enables examination of the reflection of light shone over the epidermal surface without actual physical contact. With the advent of technological advances and the universal availability of these instruments, we feel that they can be utilized as tools that reach beyond their initially intended use. It is recommended that clinicians adopt the custom of incorporating these tools for use in a wider scope of applications in daily practice as summarized in Table 1. The following paragraphs are examples of clinical scenarios where the instruments prove beneficial.

MATERIALS AND METHODS

Consecutive cases presenting with clinical conditions where illuminated magnification may presumably contribute additional information, the aforementioned tools assisted examination. Experience was gathered from two primary care physicians working in two separate communities. The examination was accompanied by digital photographic documentation. We report a number of diverse instances whereby this technique was employed. A literature search disclosed previous experience with supplementary otoscope use, in a number of indications and these are quoted. However, the additional exploitation of the dermoscope outside the scope of dermatological conditions is suggested here in the literature for the first time.

RESULTS

In the chosen cases where otoscopy or dermoscopy

Table 1. Unconventional uses of the dermatoscope and otoscope, some reflected in the literature.

Use	Reference
Otoscope	
Body orifices	-
Examination of intranasal cavity lesions or deformities	Bickley and Szilagyi (2003), Naimer et al. (2002), Tshcandl et al. (2009) and Alpini et al. (1986a)
Examination of skin conditions and lesions inside umbilicus	
Removal of umbilical foreign body Pediatric genital evaluation	Peyri (1993) Schulze et al. (2002), Press and Peleg (2003)
Intraurethral examination of warts	O'Brien and Luzzi (1995), Saim and Said (1992), Mishra and Ishra (2001)
Transillumination	
Scrotal sac	Bickley and Szilagyi (2003)
Cystic cutaneous lesions	
Sinuses	Binner and Schmidbauer (1978)
Finding a vein for venipuncture	Goren et al. (2001)
Other additional uses	
Anxiety reduction	-
Encouraging forced expiration	-
Dermatoscope	
Identifying retained sutures	-
Foreign body as splinters	-
Differentiation between trauma, hematoma or skin staining	-
Identification of true meatus in congenital hypospadias	-
Ectoparasite detection, demodex pediculosis somatic/eyelid, ctenocephalides	-
Speculation of hair stubs in trichomania	-
Identification of site entry of thorns and splinters	-
Progression / resolution of pathologic cutaneous processes	-
Diascopy evaluation	-
Assessment of eyelid rim for trichiasis	-
Accurate follow up of lesion size measuring lesion with glass face metric grid	-
Delineating tracing of surgical margins and distance from vital structures	-
Eyes	
Detection of strabismus, red reflex or cataract, hyphema, corneal abrasion, foreign body	-
Checking eye movements and pupil's reflex	-
Manipulation under magnification	-
Corneal foreign body extraction	-
Skin foreign body extraction (splinter, sting)	-
Hair tourniquet release	-




Figure 2. Otoloscope transillumination of the left scrotum in a case of infantile hydrocele. Notable translucency reassures that the mass is attributable to a fluid medium.




Figure 3. (A) Speck observed over patient's limb's skin surface may be difficult to assess. (B) With the magnification of the dermatoscope the flea [*Ctenocephalides felis*], is easily discernible beyond doubt.

examination was utilized "off label", they provided greater security of diagnosis.

Transillumination in primary care

1. Demonstration of hydrocele: is possible by shining the otoscope light against the scrotal wall. The transparency in this instance reassures that uni/bi-lateral enlargement of the scrotum is not attributed to a solid mass. The testes in pre-adolescents are visualized as small pea-size shadows while the surrounding elements are transilluminated well (Figure 2). In case of an intestinal loop within the testicular sac, the illumination is demonstrated by irregular shadows (Bickley and Szilagyi, 2003). There is even evidence of the advantage of transillumination of the palm for venipuncture in infants (Goren et al., 2001).
2. Maxillary sinus transillumination: is described despite its low yield of specific resolution of congestion and true infective states (Binner and Schmidbauer, 1978).

Skin surface examination

1. Borders and surface of lesions: close observation is often critical in making a correct diagnosis. The otoscope, shining light from a distance or dermatoscopic magnification of the involved skin surface upon contact is ideal for this purpose (O'Brien and Luzzi, 1995). To determine the cause of penile skin edema, observation of small mites (1 to 2 mm) may be the cause of swelling of skin at the base of the glans penis. A degree of magnification is reached with the otoscope, but complete certainty of the diagnosis can be reached with the dermatoscope applied directly over a speck suspected of being a parasite. Cat and dog fleas are difficult to differentiate from a distance. Sometimes identification of a single parasite may be a golden opportunity to disclose the etiology of a complete pathological state as multiple pruritic papulae, convincing the subject of the need for professional fumigation to eradicate flea infestation (Figure 3A and B) (Naimer et al., 2002). Entodermoscopy is a growing domain

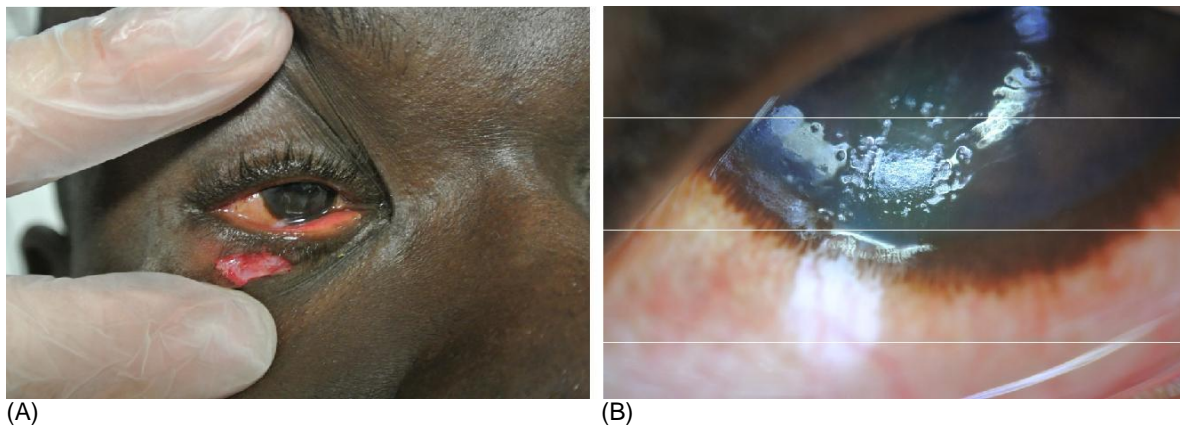


Figure 4. (A) Worker hit by a metal bar resulting in lower eyelid laceration. The integrity of the cornea is uncertain examining with the naked. (B) Polarized dermoscopy enables clear visualization of a rectangular corneal abrasion (at approximately seven o'clock) eye.

with numerous recent publications for example, scabies, tinea nigra, tungiasis, cutaneous larva migrans, ticks and reactions to spider leg spines (Tschandl et al., 2009).

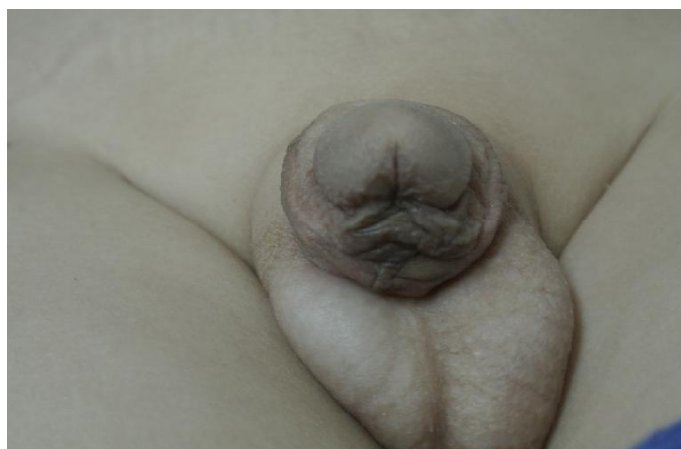Videodermoscopy has been recently employed to enhance determination of whether pediculosis or scabies parasites are either alive or dead for study purposes (Micali et al., 2011). Demodicidosis can be distinguished from rosacea, with high grade of security (Segal et al., 2010). The glass surface of the dermatoscope applied directly to any cutaneous lesion instantaneously reveals whether we meet the phenomenon of 'positive diascopy', namely, resulting in blanching if vasodilation is the key component of the process. Likewise, the grid of the contact glass enables accurate measurement of a lesion's size for documentation, future comparison and surveillance of growth dynamics.

Use of otoscope and dermatoscope for examination of the eye

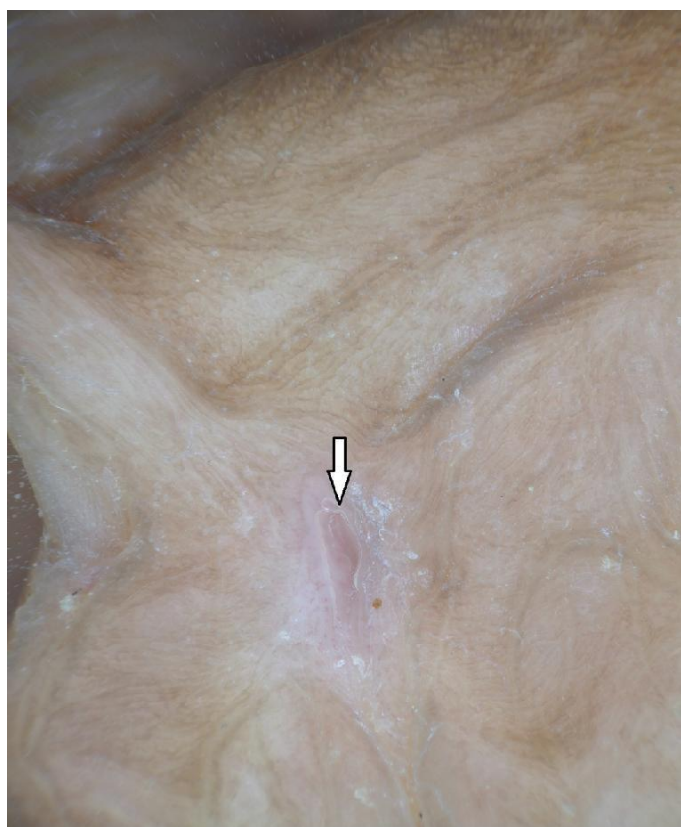1. Detection of strabismus: The "cover/uncover test" can be easily performed by using an otoscope as the source of light. Checking for red reflex is conventionally performed by checking the eyes through an ophthalmoscope with a number zero lens (Bickley and Szilagyi, 2003). If the ophthalmoscope is not available, looking through an otoscope after removing its magnifying glass component is virtually the same. Darkening the room by turning off the light is enough to produce adequate pupil dilatation. Parents of young patients are invited to observe the red reflex with the use of the otoscope and this is useful in explaining the condition to them.
2. Detection of cataract, hyphema, foreign body: These

can be detected by using the otoscope light under direct vision or alternatively illuminated at an angle from the side as with a slit lamp. The otoscope can be used in the neurological examination for assessment of the pupil reflex and eye movements just as any light source. Magnification of the tear gutter and examination of subtalar surfaces can facilitate identification of foreign body deposition.

Examination of the eye globe itself (cornea) and its nearby tender structures similar to mucosal surfaces will exclusively demand non-contact polarized dermoscopy. Eyelids are particularly difficult to assess for abnormalities while the eyelashes interfere with direct vision. Pediculosis can affect eyelids in densely populated pediatric populations. These are simply discriminated with magnification. Any irregularity of the eyelid rim arrangement of eyelashes as in trichiasis occurring after traumatic entropion or as in trachoma, or subtle appearance of dry scales in blepharitis can easily be identified by dermoscopy. Various causes of repetitive corneal trauma are discovered much sooner. When confronted by a patient presenting with a severe inflammatory conjunctival response, far from the nearest slit lamp, the ability to observe a simple corneal erosion is a great advantage (Figure 4A and B). The instant the involvement of a foreign body is reassuringly ruled out and an observed corneal abrasion can explain the patient's symptomatology, the lesion can be followed up as an outpatient with serial examinations, without referral to an ophthalmologist. If herpetic keratitis is suspected, immediate treatment can be employed. Truly, a strip of fluorescein can assist arrival at the correct diagnosis, however, its application often causes a stinging sensation



(a)



(b)

Figure 5. (a) Glanular hypospadias with unclear location of urethral meatus; (b) the arrow points to the distinct urethral meatus possible only with magnification unless fortunate micturition opportunes.

and detailed full visualization immensely enhances discrimination of the extent of the condition and allows progression surveillance.

Foreign body deposition in the cornea can escape detection unless facilitated by the polarized light of the

dermoscope. Further enlargement of the examined field is possible by operating a portable screen of a cellular telephone attached directly to the dermoscope and activating macroscopic zoom focusing. This can facilitate extrication of a foreign body from the cornea with a needle tip after topical anesthesia has been administered.

Use of otoscope and dermatoscope for examining other body orifices

The terminal speculum aspect of this instrument allows separation of opposing surfaces and at the same time examination deep into a cavity otherwise invisible. The umbilicus may be involved in every skin condition as other cutaneous surfaces. Only here, identifying the character of the disorder is only possible after using an instrument that permits visualization.

1. Detection of nasal conditions: Septum deviation in newborns and other nasal pathology such as pyramid deformation are more frequent following vaginal versus caesarean delivery (Alpini et al., 1986a, b). However, in a study from Malaysia, septal deformity was found in 21.8% of 674 newborns, with no significant relationship to the mode of delivery. The high prevalence of this pathology suggested routine screening in selected populations, as early detection may decrease future morbidity (Saim and Said, 1992). The otoscope serves as a near second if a fiberoptic endoscope is not available at least to examine the external aspect of the nasal passages. This modified otoscope examination was reported as achieving results comparable to fibro-optic sinosci endoscopy and is suggested as an inexpensive alternative for the developing world (Mishra and Mishra, 2001). The otoscope is also used to detect bleeding, polyps, mucosal colour and foreign bodies in the nose (Bickley and Szilagyi, 2003).

2. Urethra: In detection and follow-up treatment of urethral lesions (intrameatal warts, 95% are condylomata distal to the fossa navicularis), a narrow pediatric speculum of the otoscope can be inserted as deep as two centimeters into the urethra. This method is more readily available, less expensive and more comfortable than the use of flexible urethroscopy (O'Brien and Luzzi, 1995; Peyri, 1993, 1996). In cases of hypospadias, a separate pseudomeatus may exist, while the true functioning meatus may be difficult to identify unless the fortunate event of micturition occurs precisely when the baby's diaper is removed. Dermoscopy easily demarcates the functioning meatus especially when remaining urine drops appear in the opening (Figure 5A, B). All too often, we encounter meatotomy recommendations for our male pediatric patients to correct meatal stenosis without

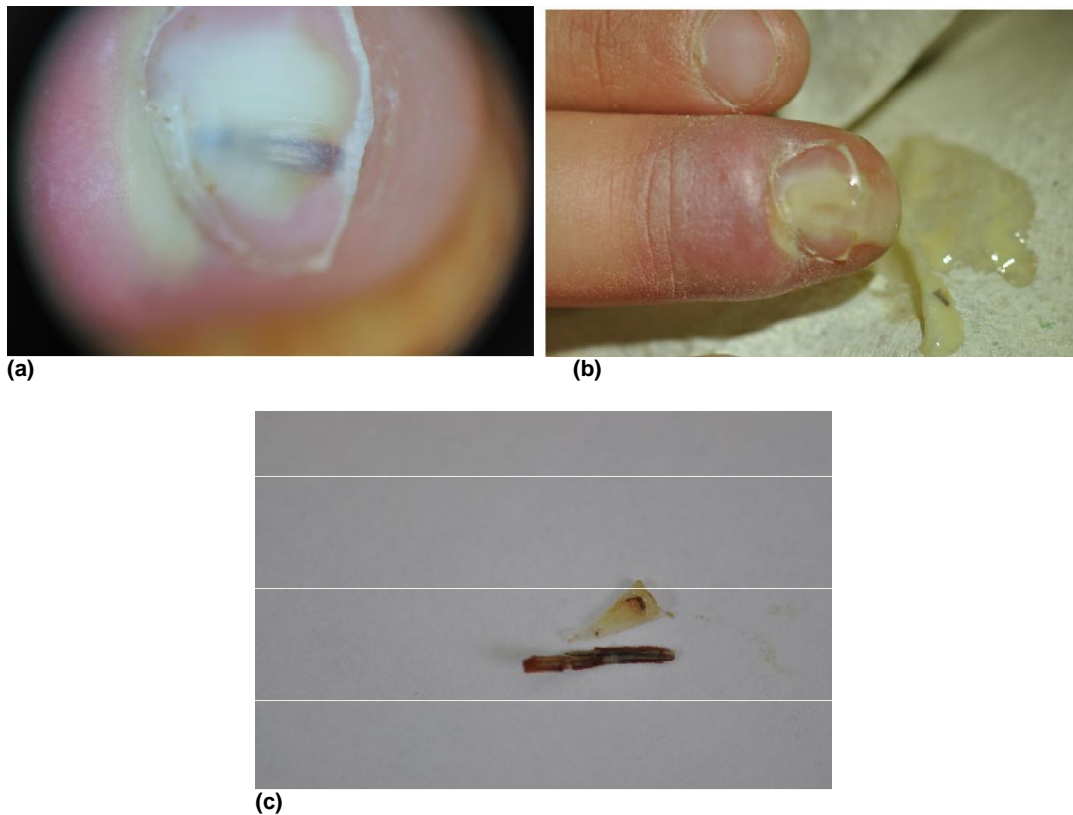


Figure 6. (a) A subungual splinter only partially adjacent to subungual surface; (b) after excision of the distal nail to expose the foreign body, the splinter is released with purulent secretion; (c) close examination shows the splinter much longer than presumed. For comparison the wedge of excised nail is shown side by side of splinter.

disclosure of a thorough history of flow and function or a consultant's testimony of escorting the toddler to the bathroom to sit and wait until the child micturates spontaneously in order to assess strength and distance of urine flow. Often, the diagnosis is erroneously made by pure examination of the meatus with the naked eye. Applying the dermatoscopic grid to the opening may allow accurate measurement of the true size of the meatus by parting regional soft tissue. This value can also assist research attempts to correlate between orifice size and actual urinary flow. Similarly, the precise opening of a preauricular fistula is easier to assess with this utensil and may disclose the source of a purulent secretion or focus on the portal of entry of an abscess formed in this area.

3. Detection and extraction of foreign bodies from body orifices: This is a common problem in general practice. The procedure of extracting a foreign body is preferably done by an otoscope with a surgical head, that is an instrument such as forceps, hemostat or the like can be inserted through the speculum during visualization. This

provides greater flexibility and better vision (Schulze et al., 2002). An otoscope was used to detect and extract a tiny splinter deep in the umbilicus of a young woman who complained of intense pain in her umbilicus (Press and Peleg, 2003). It is suggested that a similar method could be used to inspect sinuses and fistulae.

4. Investigation of sexual abuse and genital complaints in young females: This evaluation is aided by otoscopy (Emans et al., 1987; Billmire et al., 1980).

Use of the dermatoscope to identify foreign bodies

The limited size of broken pricks, thorns or glass splinters make it extremely difficult to differentiate them from normal stained skin (Figure 6A to C). Only magnification can reassure that a disturbing skin lesion is free of a foreign substance irritating the healing process. The disturbing debate of whether there may or may not exist an underlying foreign body is especially raised when dealing with a slow healing sore or wound (Figure 7A and

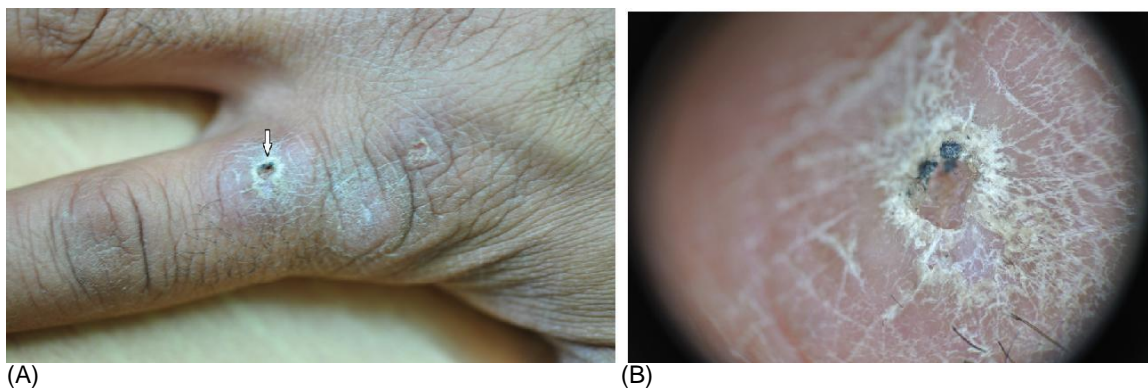


Figure 7. (A) Regular inspection can only disclose that a sore exists, with a suspicious darker colored border on one side. (B) Dermatoscopic examination provides security that the dark color is attributed to crusts without evidence of any foreign body. The sore later healed spontaneously.

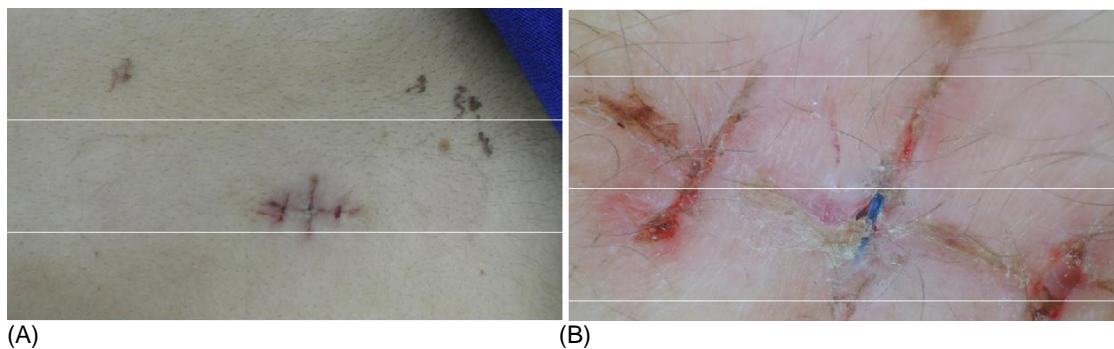


Figure 8. (A) Appearance that sutures have been removed upon regular wound review. (B) Purple colored suture remnant is discernible at the center of the middle suture track marks. (C) All too common error of removing the knot (top), while the body of the suture remained deep inside the tissue (bottom), as occurred in this case.

B). Often, upon removing sutures of a traumatic or surgical wound, uncertainty arises as to whether all sutures have been removed. In these cases, the dermatoscope is ideal for providing complete security that

the wound surface has been carefully inspected (Figure 8A to C). A common error occurs when the knot itself is cut at its base. If the cut suture is not examined to assure that the complete length of the ligature has been removed

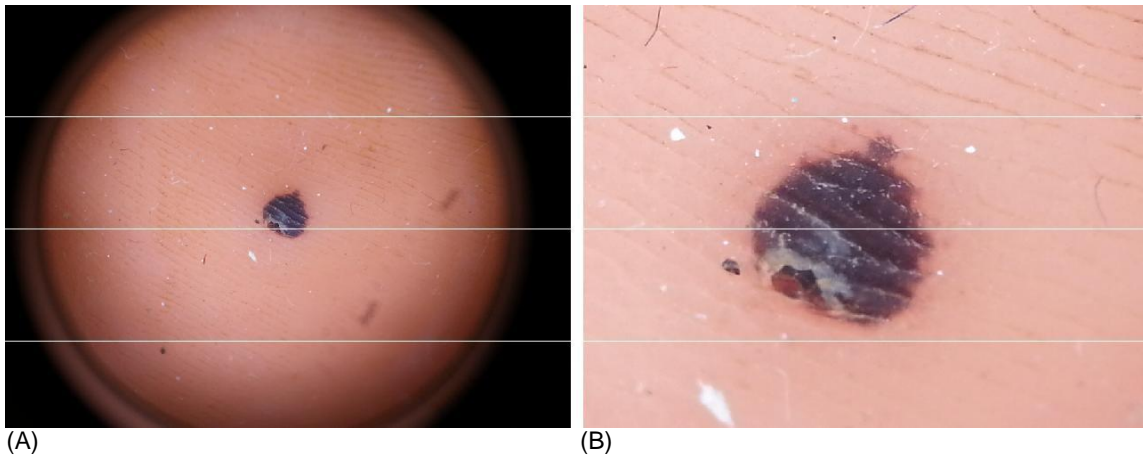


Figure 9. (A) Child with bilateral plantar black lesions. Uniform character of a hematoma involving the subcutical plane. Regular dermoscopic photography. (B) Far more convincing image of hematoma with compounded zoom enlargement of cellular telephone.

removed, the body of the suture may remain inside the tissue and stimulate a stitch granuloma or other inflammatory response. This added benefit is amplified when examining the scalp where the visual field is further obstructed by surrounding hair.

Use of the dermatoscope for characterizing non-pigmented skin lesions

Interesting enough, the original descriptions of surface microscopy derived from experience with benign superficial conditions. reported their experience with nailbed capillary vessel aberrations in pathological conditions and characterization of benign ailments as lupus vulgaris. Only later in the fifties of the last century did the wider and popular use of improving accuracy of malignancy come into play. Common applications for typifying lesions are very broad, for instance differentiation between papules. Verruca vulgaris is diagnosed easily by identifying red dots corresponding histopathologically to the apices of capillaries in the papillary dermis. These are referred to as dotted vessels that are absent in callouses. Likewise, the classic umbilication of molluscum contagiosum, milial cysts of seborrheic keratosis and the puncta of papular urticaria are diagnosed with much greater confidence provided by dermatoscopy. Nowadays there are far many indications for dermatoscopy in the field of dermatology aside from assessing pigmented lesions.

Hair is also examined easily under magnification, whereby finding stubs of broken hairs clearly differentiates trichotillomania from alopecia areata or tinea capitis.

Startling solid black lesions especially on acral surface may justifiably arouse a subjects' fear of malignancy. Here again, dermatoscopy can confirm such lesions as traumatic superficial hematoma expected to resolve spontaneously (Figure 9A and B).

Use of the dermatoscope for delineating surgical margins

Minor surgery incision borders may be challenging to plan especially when dealing with cutaneous lesions close to vital structures, for example the eyelid or close to the urethra. Likewise the position of presurgical tracing of the planned surgical margins can be greatly facilitated by dermoscopic magnification to assure that the lesion border is safe, with ample distance from tissue demanding preservation (Figure 10A and B).

Procedures under magnification of dermatoscope

In a number of instances, we may exercise the privilege of performing minor procedures hardly possible under conditions of naked eye observation. Furthermore, the advance of polarized dermatoscopy as opposed to contact and immersion enables intervention as the examination tool lies a distance from the surface. As mentioned, a cellular telephone can be attached by an adapter to the dermatoscope. By this technique, manipulation of the body surface can be performed while watching the phone's large screen (held by an assistant) in the photography mode. This opens a number of

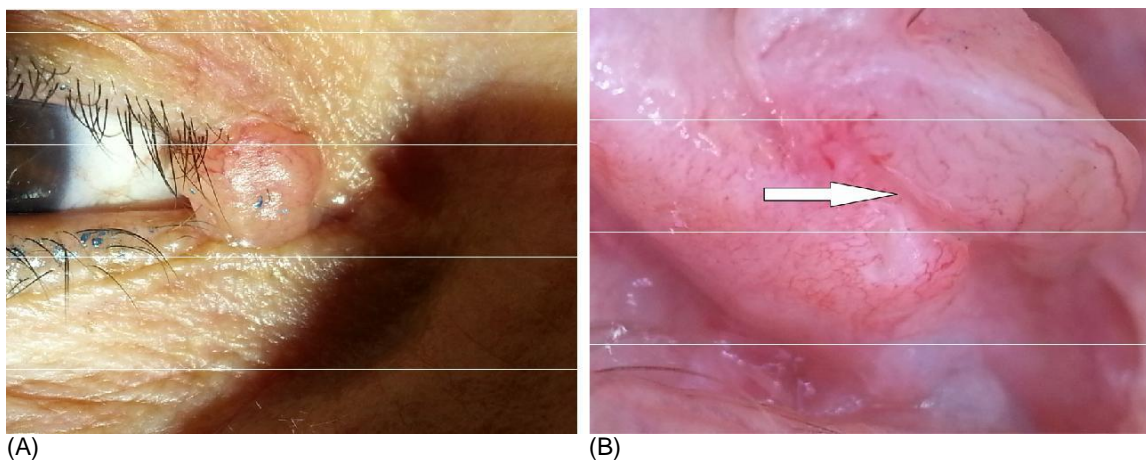


Figure 10. (A) A papular tumour aesthetically resulting in disturbance of the right inner canthus superior eyelid margin. (B) After lesion eversion, enlargement can distinctly exhibit safe distance of the tumour margin from the superior punctum of the lacrimal apparatus allowing radiosurgical excision without need for reconstruction.

opportunities for example:

1. Removal of a minute splinter such as cactus spine or insect sting with needle tip (27G);
2. Extraction of a foreign body lodged in the cornea as detailed above. This will obviously demand cooperation by the patient in order to succeed;
3. Avulsion of a hair tourniquet wrapped around the digit base. With magnification only can the physician accurately introduce the sharp scalpel tip and release the culprit hair and leave the underlying soft tissue intact.

DISCUSSION

The above example descriptions together with the respective photographic illustrations demonstrates the added potential of common tools the doctor carries in his bag of tricks. Besides their role in their specialized disciplines, our experience, alongside a growing accumulation of evidence, supports that these tools can assist in the diagnosis, monitoring and treatment of any of a number of broad and diverse clinical states. While otoscopy has already been published for a number of ancillary uses, the suggested dermoscopic uses in this paper have never been mentioned before in the medical literature.

Conclusion

This paper serves to share our experience with innovative and unconventional uses of the otoscope and

dermoscope, tools that are commonly used in clinical practice. The examples we listed are not exhaustive and a vivid imagination can probably elaborate further upon the basic uses we have described. The advantage of disseminating this information is to inform physicians of the many new benefits that can be derived from equipment already immediately available to the busy physician with no specific training and at little extra cost.

REFERENCES

- Alpini D, Brusa E, Chizzini M, Bini A, Rognoni S, Corti A (1986a). Birth injuries and congenital deviation of the nasal septum in newborn infants. *Pediatr. Med. Chir.* 8:531-534.
- Alpini D, Corti A, Brusa E, Bini A (1986b). Septal deviation in newborn infants. *Int. J. Pediatr. Otorhinolaryngol.* 11:103-107.
- Bahmer FA, Rohrer C (1986). Rapid and simple macrophotography of the skin. *Br. J. Dermatol.* 114: 135-136.
- Bickley LS, Szilagyi PG (2003). *Bates' Guide to Physical Examination and History Taking*. 8th ed. Philadelphia, New York, Baltimore. 159,375,681;674705.
- Billmire ME, Farrell MK, Dina MS (1980). A simplified procedure for pediatric vaginal examination: use of veterinary otoscope specula. *Pediatrics.* 65:823-825.
- Binner WH, Schmidbauer M (1978). Fiber optic transillumination of the sinuses: a comparison of the value of radiography and transillumination in antral disease. *Clin. Otorhinolaryngol. Allied. Sci.* 3:1-11.
- Braun RP, Saurat JH, Krischer J (1999). Diagnostic pearl: unmagnified diascopy for large pigmented lesions reveals features similar to those of epiluminescence microscopy. *J. Am. Acad. Dermatol.* 41: 765-766.
- Campos-do-Carmo G, Ramos-e-Silva M (2008). Dermoscopy: basic concepts. *Int. J. Dermatol.* 47: 712-719.
- Emans SJ, Woods ER, Flagg NT, Freeman A (1987). Genital findings in sexually abused, symptomatic and asymptomatic girls. *Pediatrics* 79:778-785.
- Feldmann H (1996). History of the ear speculum. Images from the history of otorhinolaryngology, highlighted by instruments from the

- collection of the German Medical History Museum in Ingolst. *Laryngorhinootologie* 75:311-318.
- Gilje O, O'Leary PA, Baldes EY (1958). Capillary microscopic examination in skin disease. *Arch. Dermatol.* 68:136-145.
- Goldman L (1951). Some investigative studies of pigmented nevi with cutaneous microscopy. *J. Invest. Dermatol.* 16:407-426.
- Goren A, Laufer J, Yativ N, Kuint J, Ben Ackon M, Rubinshtein M, Paret G, Augarten A (2001). Transillumination of the palm for venipuncture in infants. *Pediatric. Emerg. Care* 17:130-131.
- Kravetz RE (2002). The Otoscope. *Am. J. Gastroentero.* 97:470.
- Micali G, Tedeschi A, West DP, Dinotta F, Lacarrubba F (2011) The use of videodermoscopy to monitor treatment of scabies and pediculosis. *J. Dermatol. Treat.* 22(3):133-7
- Mishra A, Mishra SC (2001). Cost-effective diagnostic nasal endoscopy with modified otoscope. *J. Laryngol. Otol.* 115:648-649.
- Naimer SA, Cohen A, Momcoglou K, Vardy D (2002). Household papular urticaria. *Isr. Med. Ass. J.* 4:911-913.
- O'Brien TS, Luzzi GA (1995). Improving visualization of intrameatal warts: use of the otoscope. *Br. J. Urol.* 75: 793.
- Peyri RE (1993). The otoscope in the diagnosis and control of condylomata of navicular fossa: preliminary study. *Arch. Esp. Urol.* 46:321-323.
- Peyri RE (1996). Improving visualization of intrameatal warts: use of the otoscope. *Br. J. Urol.* 77: 619.
- Press Y, Peleg R (2003). Use of otoscope just for the ear? *Israel. J. Fam. Med. (Hebrew).* 13:101.
- Saim L, Said H (1992). Birth trauma and nasal septal deformity in neonates. *J. Singapore. Paediatr. Soc.* 34:199-204.
- Saphier J (1920). Die Dermatoskopie. I. Mitteilung. *Arch. Dermatol. Syphilol.* 128:1-19.
- Schulze SL, Kerschner J, Beste D (2002). Pediatric external auditory canal foreign bodies: a review of 698 cases. *Otolaryngol. Head. Neck. Surg.* 127:73-78.
- Segal R, Mimouni D, Feuerman H, Pagovitz O, David M (2010). Dermoscopy as a diagnostic tool in demodicidosis. *Int. J. Dermatol.* 49(9):1018-1023.
- Tschandl P, Argenziano G, Bakos R, Gourhant JY, Hofmann-Wellenhof R, Kittler H, Rosendahl C, Minas S, Zalaudek I (2009). Dermoscopy and entomology (entomodermoscopy). *J. Dtsch Dermatol. Ges.* 7(7):589-596.