



REVIEW

Examination and control process of oral mucocele

Madhavadiya Shaurya, Krishna Dhruv and Kabir Raahithya

Indian Institute of Technology Roorkee

Accepted 14 August, 2018

Mucocele are common salivary gland disorder which can be present in the oral cavity, appendix, gall bladder, paranasal sinuses or lacrimal sac. Common location for these lesions in oral cavity is lower lip however it also presents on other locations like tongue, buccal mucosa, soft palate, retromolar pad and lower labial mucosa. Trauma and lip biting habits are the main cause for these types of lesions. These are painless lesions which can be diagnosed clinically. In this review, a method used for searching data includes various internet sources and relevant electronic journals from the Pub Med and Medline.

Keywords: Mucocels, Lower lip, Retention cyst.

INTRODUCTION

Mucocele is defined as a mucus filled cyst that can appear in the oral cavity, appendix, gall bladder, paranasal sinuses or lacrimal sac (Baumash, 2003; Ozturk et al., 2005). The term mucocele is derived from a latin word, mucus and cocele means cavity (Yagüe-García et al., 2009). Mucocele is seventeenth most common salivary gland lesions seen in the oral cavity (Flaitz and Hicks, 2006). This is the result of accumulation of mucus due to the alteration in the minor salivary gland which causes limited swelling (BagánSebastián et al., 1990)

In this review, a method used for searching data from includes various internet sources and relevant electronic journals from the Pub Med and Medline.

Types

Clinically there are two types, extravasation and retention type. Extravasation type is due to the leaking of fluid from the salivary gland ducts and acini to surrounding soft tissues. This type of mucocele is seen in minor salivary glands.

Retention type is due to the obstruction of salivary gland duct and is commonly seen in major salivary gland ducts (Boneu-Bonet et al., 2005) Clinically there is no difference between extravasation and retention type of mucocele. When the mucocele is located in floor of the mouth it appears as 'cheeks of a frog' and called as ranula (Boneu-Bonet et al., 2005)

These lesions are devoid of epithelial lining and are also termed as,

- Superficial mucocele
- Classical mucocele.

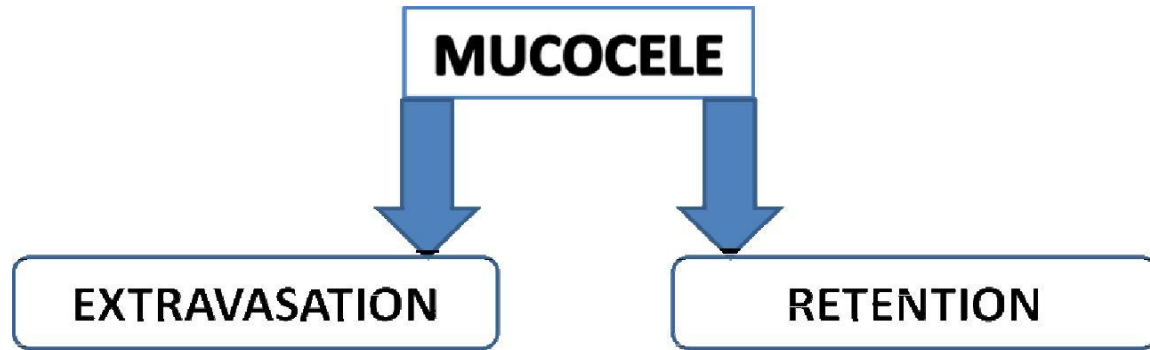


Figure 1. Provide legend

Superficial mucocele are located under the mucous membrane and classical mucocele are seen in the upper submucosa (Baurmash, 2003; Selim and Shea, 2007).

Etiopathogenesis

The two important etiological factors are (Yamasoba et al., 1990)

- I. Trauma and
- II. Obstruction of salivary gland duct.

Mainly physical trauma causes a spillage of salivary secretion into surrounding submucosal tissue. Later inflammation may become obvious due to stagnant mucous (Boneu-Bonet et al., 2005). Habit of lip biting and tongue thrusting are also one of the aggravating factors (Gupta et al., 2007).

The extravasation type will undergo three evolutionary phases (Ata-Ali et al., 2010).

- I. In the first phase there will be spillage of mucus from salivary duct into the surrounding tissue in which some leucocytes and histiocytes are seen.
- II. In second phase, granulomas will appear due to the presence of histiocytes, macrophages and giant multinucleated cells associated with foreign body reaction. This second phase is called as resorption phase.
- III. Later in third phase there will be a formation of pseudocapsule without epithelium around the mucosa due to connective cells.

The retention type of mucocele is commonly seen in major salivary glands. It is due to the dilatation of duct due to block caused by a sialolith or dense mucosa (Ata-Ali et al., 2010). It depends upon the obstruction of salivary flow from secretory apparatus of the gland (Flaitz and Hicks, 2006).

Clinical characteristics

Mucocele is the common salivary gland disorder and it is the second most common benign soft tissue tumor in the oral

cavity (Baurmash, 2002). It is characterised by accumulation of mucoid material with rounded, well circumscribed transparent, bluish coloured lesion of variable size. It is a soft and fluctuant asymptomatic swelling with rapid onset which frequently resolves spontaneously (Eveson, 1988; Bermejo et al., 1999). Common in the lower lip but may occur in other locations also. [14]. The bluish discoloration is mainly due to the vascular congestion and cyanosis of the tissue above and the fluid accumulation below.

It also depends on the size of the lesion, proximity to the surface and upper tissue elasticity (Baurmash, 2003; Bentley et al., 2003).

Size may be few millimeters to centimeters and occurs singly and rarely bilateral (Flaitz and Hicks, 2006; López-Jornet, 2006). They are usually dome shaped swellings with intact epithelium over it (Figure 2, 3, 4). Sometimes superficial mucocele with single or multiple blisters seen on the soft palate, retromolar pad, posterior buccal mucosa and lower labial mucosa rupture spontaneously and become ulcerated mucosal surface and heals within few days (Gupta et al., 2007).

It seen equally in men and women. It is common in first three decade of life (Selim and Shea, 2007). The differential diagnosis which can be considered are Blandin and Nuhnmucocele, Benign or malignant salivary gland neoplasms, oral hemangioma, oral lymphangioma, Venous varix or venous lake, lipoma, soft irritation fibroma, oral lymphoepithelial cyst, gingival cyst in adults, soft tissue abscess, cysticercosis. Superficial mucocele may be confused with cicatricial pemphigoid, bullous lichen planus and minor aphthous ulcers (Gupta et al., 2007).

Diagnosis

The appearance of mucocele is pathognomonic so the data about the lesion location, history of trauma, rapid appearance, variations in size, bluish colour and the consistency helps in diagnosis of such lesions (Bentley et al., 2003; Andiran et al., 2001; Guimaraes et al., 2006).

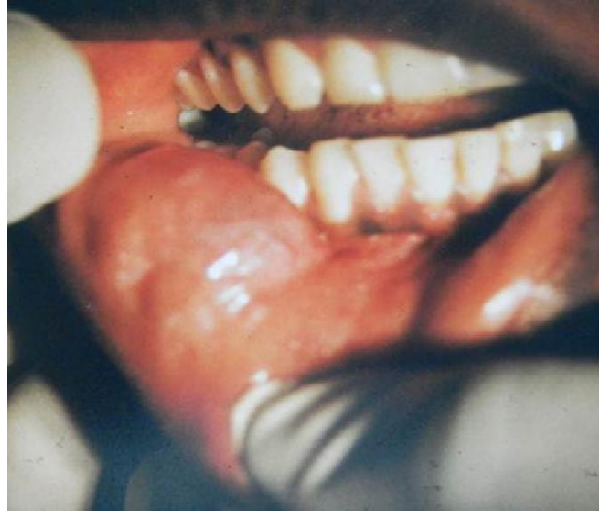

Figure 2. Mucocele on the right side of the lower lip

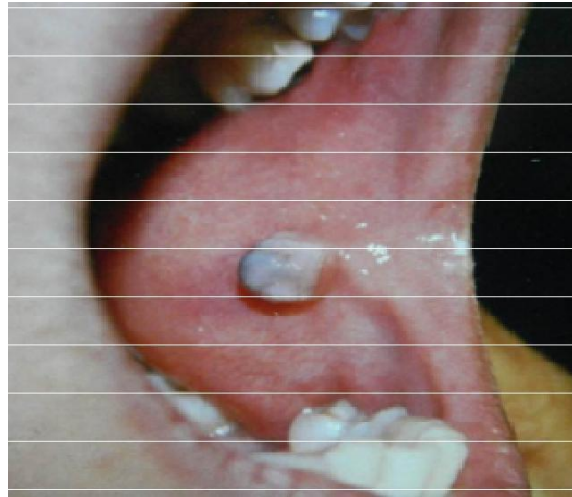

Figure 3. Mucocele on the left side of the buccal mucosa

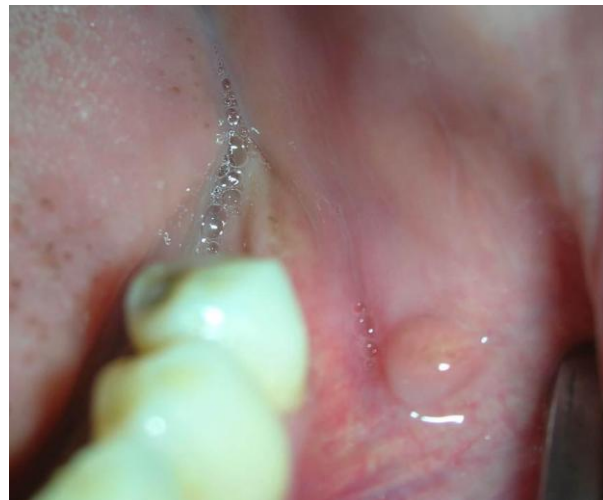

Figure 4. Mucocele on the left side buccal sulcus

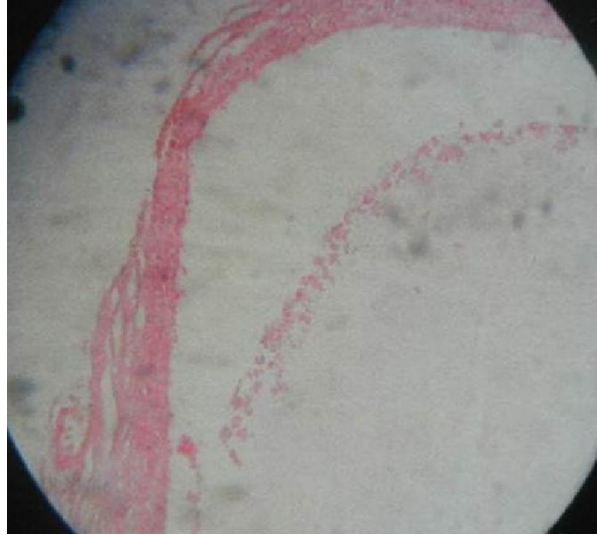

Figure 4. Photomicrograph showing ductal epithelium and inflammatory cells

Usually this lesion has a soft and elastic consistency which depends on tissue present over the lesion (Bentley et al., 2003). History and clinical findings will lead to the diagnosis in case of superficial mucocele. Fine needle aspiration demonstrates the mucus retention, histiocytes and inflammatory cells (Layfield and Gopez, 2002). In retention type mucoceles, cystic cavity with well-defined epithelial wall lined with cuboidal cells are present. This type shows less inflammatory reaction (Guimarães et al., 2006). The extravasation type is a pseudocyst without epithelial wall and shows inflammatory cells and granulation tissues (Guimarães et al., 2006). Chemical analysis of saliva shows high amylase and protein content.

Radiographs are the contributing factors in diagnosis of ranulas. Localization of these lesions is done by computed Tomography and Magnetic Resonance Imaging (Gupta et al., 2007). Histopathologically it shows ductal epithelium, granulation tissue, pooling of mucin and inflammatory cells (Figure 5)

Treatment

Conventional surgical removal is the most common method used to treat this lesion. Other treatment options include CO₂ laser ablation, cryosurgery, intralesional corticosteroid injection, micro marsupialization, marsupialization and electrocautery (López-Jornet and Bermejo-Fenoll, 2004; Ishida and Ramos-e-Silva, 1998; Kopp and St-Hilaire, 2004; García et al., 2009). Some studies suggested that the initial cryosurgical approach or intralesional corticosteroid injection in the treatment of these lesions but cases of relapses in these techniques is more (García et al., 2009). There is no difference in the

treatment of retention and extravasation mucocele. Small sized mucoceles are removed with marginal glandular tissue and in case of large lesions marsupialization will help to avoid damage to vital structures and decrease the risk of damaging the labial branch of mental nerve (García et al., 2009). Lacrimal catheters are used to dilate the duct to remove the obstruction of retention type mucoceles (Baumash, 2003; Gupta et al., 2007). While removing the mucocele surgically, remove the surrounding glandular acini. removing the lesion down to the muscle layer and avoiding the adjacent gland and duct damage while placing the suture will reduce the chances of recurrence (Baumash, 2003; Huang et al., 2007). Removal of surrounding glandular acini, excision or dissection of lesion down to the muscle layer and avoiding damage to adjacent gland and duct are some strategies to reduce recurrence. If the fibrous wall of the mucocele is thick, then the removed tissue must be sent for histopathological examination to rule out any salivary gland neoplasms (Gupta et al., 2007).

The micromarsupialization is considered as an ideal treatment in case of pediatric patient because this technique is simple, rapid and less chances of recurrence (Delbem et al., 2000).

The advantage in CO₂ laser is it minimizes the recurrences and complications and allows rapid, simple mucocele ablation. It is also indicated for the patients who cannot tolerate long procedures (García et al., 2009).

CONCLUSION

Mucocele is the most common benign self-limiting condition. It is commonly seen in young males. Trauma is

the most common cause and majority of these lesions are seen in lower lips. Majority of these cases can be diagnosed clinically however sometimes biopsy is required to rule out any other types of neoplasm. There are various treatment options available but the CO₂ laser treatment shows more benefits and less relapses. There are various treatment options available but the CO₂ laser treatment is a better option with the least chances of recurrence. Since these lesions are painless, it is the dentists, who usually pick up these lesions when the patient comes for a routine oral check or an unrelated dental problem,

REFERENCES

- Andiran N, Sarikayalar F, Unal OF, Baydar DE, Ozaydin E (2001). Mucocele of the anterior lingual salivary glands: from extravasation to an alarming mass with a benign course. *Int J Pediatr Otorhinolaryngol.* 61:143-47.
- Ata-Ali J, Carrillo C ,Bonet C , Balaguer J, Peñarrocha M , Peñarrocha M (2010). Oral mucocele: review of the literature. *J ClinExp Dent.* 2:e18-21.
- BagánSebastián JV, Silvestre Donat FJ, PeñarrochaDiago M, MiliánMasanet MA (1990). Clinico-pathological study of oral mucoceles. *Av Odontoestomatol.* 6:389-91, 394-95.
- Baurmash H (2002). The etiology of superficial oral mucoceles. *J Oral Maxillofac Surg.* 60:237-8.
- Baurmash HD (2003). Mucoceles and ranulas. *J Oral Maxillofac Surg.* 61:369-78.
- Bentley JM, Barankin B, Guenther LC (2003). A review of common pediatric lip lesions: herpes simplex/recurrent herpes labialis, impetigo, mucoceles, and hemangiomas. *ClinPediatr (Phila).* 42:475-82.
- Bermejo A, Aguirre JM, López P, Saez MR (1999). Superficial mucocele:report of 4 cases. *Oral Surg Oral Med Oral Pathol Oral Radiol Endod.* 88:469-72.
- Boneu-Bonet F, Vidal-Homs E, Maizcurrana-Tornil A, González-Lagunas J (2005). Submaxillary gland mucocele: presentation of a case. *Med Oral Patol Oral Cir Bucal.* 10:180-84.
- Delbem AC, Cunha RF, Vieira AE, Ribeiro LL (2000).“ Treatment of mucus retention phenomena in children by the micro-marsupialization technique: case reports. *Pediatr Dent.* 22:155-58.
- Eveson JW (1988). Superficial mucoceles: pitfall in clinical and microscopic diagnosis. *Oral Surg Oral Med Oral Pathol.* 66:318-22.
- Flaitz CM, Hicks JM (2006). Mucocele and ranula.eMedicine. Retrieved 19 October from <http://www.emedicine.com/derm/topic648.htm>
- García JY, Tost AJE, Aytés LB, Escoda CG (2009). Treatment of oral mucocele - scalpel versus CO₂ laser. *Med Oral Patol Oral Cir Bucal.* 14 :e469-74.
- Guimarães MS, Hebling J, Filho VA, Santos LL, Vita TM, Costa CA (2006). Extravasationmucocele involving the ventral surface of the tongue (glands of Blandin-Nuhn). *Int J Paediatr Dent.* 16:435-39.
- Gupta B, Aneundi R, SudhaP,Gupta M (2007). Mucocele:Two Case Reports. *J Oral Health Comm Dent* 1:56-58
- Huang IY, Chen CM, Kao YH, Worthington P (2007). Treatment of mucocele of the lower lip with carbon dioxide laser. *J Oral Maxillofac Surg.* 65:855-58.
- Ishida CE and Ramos-e-Silva M (1998). Cryosurgery in oral lesions. *Int J Dermatol.* 37: 283-85.
- Kopp WK, St-Hilaire H (2004). Mucosal preservation in the treatment of mucocele with CO₂ laser. *J Oral Maxillofac Surg.* 62: 1559-61.
- Layfield LJ, Gopez EV (2002). Cystic lesions of the salivary glands: cytologic features in fine-needle aspiration biopsies. *DiagnCytopathol.* 27:197-204.
- López-Jornet P (2006). Labial mucocele: a study ofeighteen cases. *The Internet Journal of Dental Science.* 3(2). Retrieved 7 February 2007, from <http://www.ispub.com/ostia/index.php?xmlFilePath=journals/ijds/vol3n2/labial.xml>.
- López-Jornet P, Bermejo-Fenoll A (2004). Point of Care: What is the most appropriate treatment for salivary mucoceles? Which is the best technique for this treatment? *J Can Dent Assoc.* 70: 484-85.
- Ozturk K, Yaman H, Arbag H, Koroglu D, Toy H (2005). Submandibular gland mucocele: report of two cases. *Oral Surg Oral Med Oral Pathol Oral RadiolEndod.* 100:732-35.
- Seifert G, Miehke A, Haubrich J, Chilla R (1986). Diseases of the salivary glands. Stuttgart: GeorgThieme Verlag. pp. 91-100.
- Selim MA, Shea CR (2007). Mucous cyst.eMedicine. Retrieved 7 February from:<http://www.emedicine.com/derm/topic274.htm>.
- Yagüe-García J, España-Tost AJ, Berini-Aytés L, Gay-Escoda C (2009). Treatment of oral mucocele - scalpel versus CO₂ laser. *Med Oral Patol Oral Cir Bucal.* 14 :e469-74.
- Yamasoba T, Tayama N, Syoji M, Fukuta M (1990). Clinicostatistical study of lower lip mucoceles. *Head Neck.* 12:316-20.