

*Full Length Research Paper*

# Effect of *Commiphora swynnertonii* resin extract on various physiological parameters in chickens

**Tiggs Membe\*, Reginald Bernand and Joseph Mengi**

Faculty of Veterinary Medicine, Sokoine University of Agriculture, P. O. Box 3017, Morogoro, Tanzania.

Accepted 19 May, 2016

In the current study, various haematological and biochemical parameters of chickens were evaluated following an oral administration of resin extract from *Commiphora swynnertonii*. Sixty chickens (8 months old) were randomly assigned into 5 groups (n=12): G1 served as a negative control, that is, chickens received normal saline only, while G2 to G5 chickens were given different doses of the resin extract orally for 14 consecutive days. Results revealed no signs of sickness or death in groups G1, G2 and G3 throughout the experimental period of 28 days. The body weights of chickens in G2, G3, G4 and G5 decreased significantly in a dose dependent manner from day 3 of treatment with the resin. The resin administration did not affect packed cell volume (PCV), total white blood cell (WBC) count, differential WBC count (heterophils and eosinophils). However, haemoglobin (Hb), total red blood cell (RBC) count, mean corpuscular hemoglobin (MCH) and mean corpuscular hemoglobin concentration (MCHC) decreased significantly ( $P < 0.05$ ) with increasing concentration of the resin. Significant dose dependent reduction ( $P < 0.01$ ) in plasma glucose and total cholesterol was observed. Levels of total protein, albumin and globulin in the resin-treated groups were not significantly affected. In the current study, liver transaminases (alanine transaminase (ALT) and aspartate aminotransferase (AST)) levels increased slightly to a maximum peak by day 21-post treatment. It is concluded that administration of the resin extract in chickens caused no undesirable effects at lower doses, but with increased doses signs of toxicity were evident. It is therefore suggested that, before the resin extract can be used for veterinary or medical purposes, safety margin must be established for each animal species in question.

**Key words:** *Commiphora swynnertonii*, haematological parameters, biochemical parameters, resin extract, treatment, chicken.

## INTRODUCTION

Plants have been recognized as indispensable sources of both preventive and curative traditional medicine preparations for human beings and livestock since time immemorial (Dharmananda, 2003; Adnan et al., 2010).

According to World Health Organization, approximately 80% of the world's inhabitants use traditional medicines, particularly herbal preparations (WHO, 2007). In some countries, the use of herbal preparations is being

\*Corresponding author: E-mail: [tiggs.membe@gmail.com](mailto:tiggs.membe@gmail.com)

Author(s) agreed that this article remain permanently open access under the terms of the Creative Commons Attribution License 4.0 International License

gradually integrated into the primary and secondary health care systems (El-Mahmood and Ameh, 2007). As a result of this increased interest, research on traditional medicines is on the rise as manifested by plenty of scientific literature on antimicrobial activity of plants and their secondary metabolites (Adnan et al., 2010).

*Commiphora swynnertonii* which belong to the family Burseraceae is among plants that claimed to have a broad spectrum of medicinal activities. In Tanzania, various parts of this plant are used for treatment of health related problems including wounds, diarrhoea, respiratory ailments and intestinal parasites (Kaoneka et al., 2002). Recently, resin from *C. swynnertonii* was shown to have strong activity against New Castle disease virus, bacteria and coccidian parasites in chickens (Bakari et al., 2012a, b, 2013). Despite of these promising results and the fact that *C. swynnertonii* resin is widely used in Tanzania, there is no scientific documentation on safety and/or any adverse effects associated with its use both in humans and animals. This study was therefore designed and carried out to investigate any side effects that could be associated with administration of the resin in chickens. In particular, selected internal organs, biochemical and haematological parameters were examined following administration of varying loads of the resin in growing chickens.

## MATERIALS AND METHODS

### *C. swynnertonii* resin extract

Resinous material from *C. swynnertonii* tree was collected, extracted and preserved as described by Parekh and Chanda (2006). Briefly, 500 g of the resinous material were soaked in 1,000 ml of ethanol (99.8% v/v) in a conical flask plugged with aluminium foil and kept for 2 h in a dark place at room temperature. After soaking, the suspension was filtered using Whatmann® filter paper No. 1. The filtrate was concentrated on water bath at 50°C using a rotary evaporator (BUCHI, Switzerland). The resulting crude resin extract was stored at 4°C in airtight bottles until used.

### Experimental animals and housing

Healthy chickens (Black Australorp) of 8 months old were purchased from commercial farmers in the township of Morogoro. The chickens were caged in pairs and maintained on a basal feed of growers mash, with mineral supplements (Amintotal®) and *ad libitum* access to drinking water. All chickens were dewormed and vaccinated against Newcastle (ND) and Infectious Bursal disease (IBD); they were also assessed for any signs of diseases. The chickens were left for three weeks to acclimatize with experimental environment. Following acclimatization, they were weighed, wing tagged and randomly assigned into five experimental groups of 12 chickens each.

### Experimental design

Treatment allocations are shown in Table 1. Groups 2 to 5 chickens were given different doses of aqueous resin extract orally by means of a 5-ml plastic syringe once a day for 14 consecutive days. Group

1 remained as negative control, that is, chickens that received normal saline only. Immediate and extended signs of toxicity and changes in body weight were observed. Blood samples were collected for evaluation of haematological and biochemical parameters.

### Collection of blood for haematological and biochemical parameters

Blood samples (approximately 3 ml) were collected from wing veins using syringe and 23G needle at regular interval from day 0, 3, 7, 14, 21 and 28. About 1 ml blood was then transferred into blood sample bottles containing EDTA for haematological parameters analysis, while the remaining 2 ml were immediately centrifuged at 3000 rpm for 10 min to obtain fresh plasma, which was used for analysis of biochemical parameters. To avoid diurnal variability, sampling was carried out in the morning between 7 and 9 a.m.

### Determination haematological parameters

These parameters were determined as described by Fudge (2000). Briefly, packed cell volume (PCV) was determined using a Hawksley haematocrit reader. Enumeration of erythrocytes and leucocytes was carried out using an improved Neubauer haematocytometer. Haemoglobin (Hb) was determined by spectrophotometer at 540 nm. Cellular characterization involved staining of blood smears with Giemsa followed by microscopic examination of not less than 50 fields.

### Determination of biochemical parameters

Determination of blood glucose and cholesterol levels was done as explained by Trinders et al. (1969). Total protein was determined by Biuret method as described by WHO (2006). Albumin was measured by bromocresol green based on principles described by Bush (1991). Liver enzymes (alanine transaminase (ALT) and aspartate aminotransferase (AST)) were determined by the kinetic methods described by International Federation of Clinical Chemistry without pyridoxal phosphate. Creatinine was determined by colorimetric method using Jaffe Elitech® kits.

### Post mortem examination

Chickens were humanly killed and tissue sections of muscles, liver, kidney and intestines were preserved for histopathological examination. The preserved tissues were processed as described by Drury and Wallington (1976).

### Data analysis

Haematological results were presented as mean  $\pm$  standard error of mean (SEM). One way analysis of variance (ANOVA) was used to determine significance between tests and controls. P-values less than 0.05 were considered significant.

## RESULTS

### Clinical signs

No signs of sickness or death were observed in the G1,

**Table 1.** Grouping and treatments allocation.

Group (n =12)	Treatment given once daily for 14 days
G1	Control (not given resin extract)
G2	250 mg resin/kg
G3	500 mg resin/kg
G4	750 mg resin/kg
G5	1000 mg resin/kg

G2 and G3 group throughout the experimental period of 28 days. Twenty one percent (5/24) of chickens from G4 and G5 showed signs of dullness and voided loose whitish faeces. These signs were evidently seen from day 7 of resin treatment.

### Mean body weights

Mean body weights of chickens in G1 increased gradually ( $P < 0.001$ ) throughout the experimental period compared to resin treated groups. From day 3 of the treatment, the body weights of chickens in G2, G3, G4 and G5 decreased significantly in a dose dependent manner ( $R^2 = 0.85$ ;  $P = 0.02$ ). From day 14 post treatment, the mean body weights were almost constantly decreased till the end of experimental period.

### Haematological parameters

Haematological parameters are shown in Table 2. PCV values of chickens in the negative control group (G1) were significantly higher ( $P < 0.05$ ) compared to those of resin-treated groups (G2, G3, and G5). There was no significant difference in the levels of PCV among the resin treated groups. Hb levels for all treated groups were significantly ( $p < 0.001$ ) lower than that of the negative control group (G1). Similar trend was observed with total red blood cell count (RBC) count whereby the levels for all groups treated with aqueous resin extract were lower than that of G1.

The values for the calculated MCH were observed to be significantly higher in G2 and G5 as compared other treated groups. While the MCHC was observed to decrease in all groups but more the decrease was highly noted in G2 and G5. Total white blood cell (WBC) count of chickens in G1 and G2 was significantly lower ( $p < 0.001$ ) as compared to G3, G4 and G5. This significant difference was attributed to increased levels of monocytes and lymphocytes compared to other cells such as heterophils and eosinophils. The levels of heterophils and eosinophils were similar in all groups regardless of the treatment given (Figures 1 and 2).

### Biochemical parameters

Plasma glucose levels of chickens treated with aqueous

resin extract are shown in Figure 3. Daily treatment with resin extract at dosages of 250, 500, 750 and 1000 mg/kg produced significant ( $P < 0.01$ ) decrease in the plasma glucose levels. This decrease in plasma glucose level was dose and time dependent ( $R^2 = 0.83$ ;  $p = 0.01$ ). For instance, the glucose levels on day 7 after the last resin dose was 228.3 to 110.0 mg/dl and 222.4 to 138.0 mg/dl for G4 and G5, respectively.

The total plasma cholesterol decreased in a dose dependent manner as shown in Figure 4. By day 3 of treatment, levels in the treated groups were significantly ( $p < 0.01$ ) lower than that of the negative control group (G1). There was a negative correlation between the increase in doses of resin with that of plasma total cholesterol level (correlation coefficient = - 0.84).

The resin extract did not induce any significant variations in the levels of total plasma protein including those of albumin and globulin. That is, similar patterns were observed across the groups regardless of resin treatment. Mostly, the total protein values ranged from  $4.4 \pm 0.3$  to  $5.9 \pm 0.5$  g/dl. For instance, levels of all the three parameters in all groups were the lowest around day 15 of treatment and increased steadily towards the end of observation period.

The effect of the extract on liver function markers (ALT and AST) was not significant although between days 14 and 21 levels in G3, G4 and G5 were slightly higher ( $P = 0.08$ ) than in the control group. For instance, the trends of ALT in G3 ranged from  $30.4 \pm 3.0$ ,  $48.6 \pm 4.6$  and  $50.3 \pm 6.5$  IU/L from day 0, 7 and 14, consecutively. Similarly, AST in the same group had the same trend which ranged from  $113.5 \pm 13.2$ ,  $122.9 \pm 9.8$ ,  $128.2 \pm 11.0$  and  $141.6 \pm 12.3$  IU/L from day 0, 7 and 14, consecutively, though the levels in all groups were within the normal range.

Plasma creatinine levels increased in a dose dependent manner for all treated groups as compared to the negative control groups. The levels were significantly ( $P < 0.01$ ) increased from day 7 of treatment. Uric acid levels did not differ significantly ( $P > 0.05$ ) among treated groups, although the increased level was seen from last day of treatment with resin extract. For plasma creatinine and uric acid, the levels resumed immediately to the normal level following cessation of resin administration.

### Pathological and histopathological findings

Two chickens from each group were sacrificed and examined for visual and histopathological lesions in selected organs and tissues. Liver of chickens in G4 showed marked enlargement with numerous yellowish patches of different sizes (mottling appearance).

No visual changes were observed in the intestines, kidneys, lungs, spleen, muscles in normal and chickens treated with resin extract at doses lower than 500 mg/kg. Histopathological results showed structural damage to the liver and kidney tissues of chickens treated with 250 and 500 mg extract per kg bodyweight. However, at higher

**Table 2.** Mean haematological parameters of chickens following oral administration of *C. swynnertonii* resin extract.

Parameter	Day	Group				
		G1	G2	G3	G4	G5
PCV (%)	0	23.0 ± 1.1	24.2 ± 0.7	24.9 ± 0.8	24.2 ± 0.8	26.2 ± 1.0
	14	26.8 ± 1.5*	24.8 ± 0.7	23.9 ± 1.4	21.9 ± 1.4	24.2 ± 1.4
Hb (g/dl)	0	8.1 ± 0.4	7.9 ± 0.8	8.2 ± 0.4	7.9 ± 0.4	9.1 ± 0.4
	14	8.5 ± 0.3	6.3 ± 0.5*	5.6 ± 0.5**	5.5 ± 0.5**	5.4 ± 0.5***
RBC count (×10 <sup>6</sup> µL)	0	3.9 ± 0.4	3.7 ± 0.2	3.8 ± 0.2	3.6 ± 0.2	3.9 ± 3.0
	14	3.9 ± 0.1	2.8 ± 0.3*	2.8 ± 0.1**	2.3 ± 0.2**	1.9 ± 0.3***
MCH (pg/cell)	0	21.9 ± 1.7	21.4 ± 1.8	21.4 ± 1.6	22.2 ± 1.8	25.3 ± 2.5
	14	21.7 ± 1.2	26.4 ± 4.2*	22.7 ± 1.7	24.7 ± 2.4	37.4 ± 6.9*
MCHC (%)	0	36.8 ± 3.4	33.1 ± 3.1	33.0 ± 2.7	32.7 ± 1.4	35.4 ± 2.4
	14	32.7 ± 2.3	23.5 ± 2.1*	28.9 ± 4.3	28.7 ± 2.8	23.0 ± 2.2**
Total WBC (×10 <sup>3</sup> µl)	0	1.8 ± 0.2	1.5 ± 0.2	1.1 ± 0.2	1.7 ± 0.1	2.1 ± 0.3
	14	1.7 ± 0.2	1.5 ± 0.1	1.7 ± 0.1	2.0 ± 0.1	2.2 ± 0.3
Lymphocytes (%)	0	57.2 ± 1.9	57.5 ± 1.7	57.5 ± 1.7	54.9 ± 2.1	56.6 ± 2.1
	14	57.1 ± 1.9	61.3 ± 2.4*	60.5 ± 2.7*	63.0 ± 2.1**	62.5 ± 1.8**
Heterophils (%)	0	32.1 ± 1.7	29.6 ± 1.4	30.5 ± 2.1	29.6 ± 1.4	29.6 ± 1.4
	14	26.8 ± 1.6	30.2 ± 1.9	30.3 ± 1.6	31.2 ± 1.8	32.8 ± 1.6
Monocytes (%)	0	7.0 ± 0.5	6.0 ± 0.4	5.9 ± 0.7	6.0 ± 0.5	5.3 ± 0.4
	14	6.8 ± 0.4	7.6 ± 0.4*	8.3 ± 0.3***	7.8 ± 0.3**	7.5 ± 0.3***
Eosinophils (%)	0	3.7 ± 0.5	4.3 ± 0.5	3.3 ± 0.4	4.3 ± 0.5	4.3 ± 0.5
	14	3.8 ± 0.6	4.4 ± 0.4	3.7 ± 0.4	4.4 ± 0.4	4.4 ± 0.4

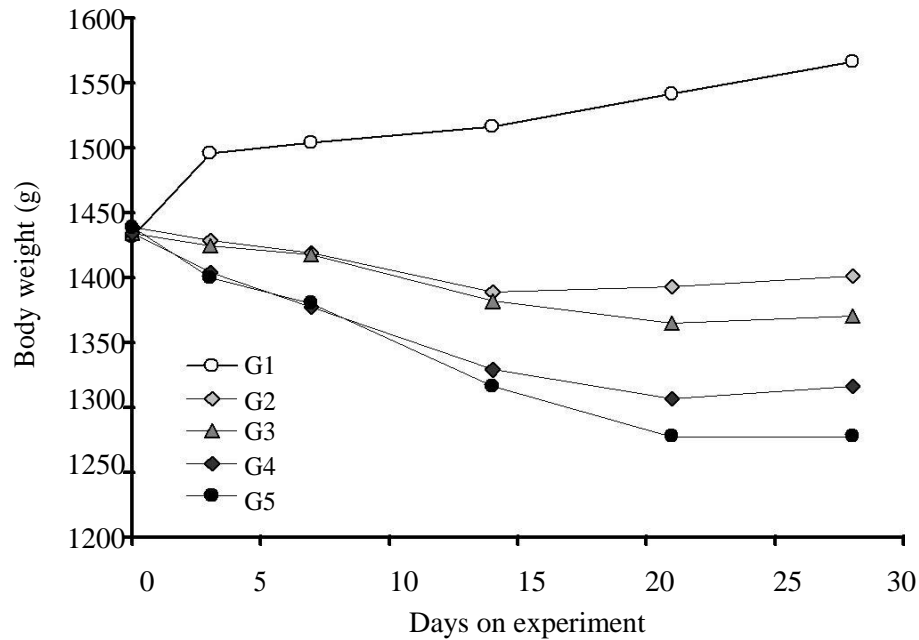
Tabulated values are the mean ± standards error of the mean for 12 determinations; \*P< 0.05; \*\* P<0.01; \*\*\*P<0.00.

doses of 750 and 1000 mg/kg, mild congestion, fatty degeneration and infiltration of mononuclear inflammatory cells around blood vessels (perivascular cuffing) was observed at subcapsular and around portal triad of the liver. In addition, cortical hemorrhages, medullary congestion, hydropic degeneration of the cortical - tubular epithelium and glomerulus were seen in the kidneys from G4. The group treated with 1000 mg/kg (G5) also showed acute glomerulonephritis, passive pulmonary congestion with mild atelectasis (collapse of alveolar tissues). Hyperplasia of lymphocytic white pulps was identified in their spleens.

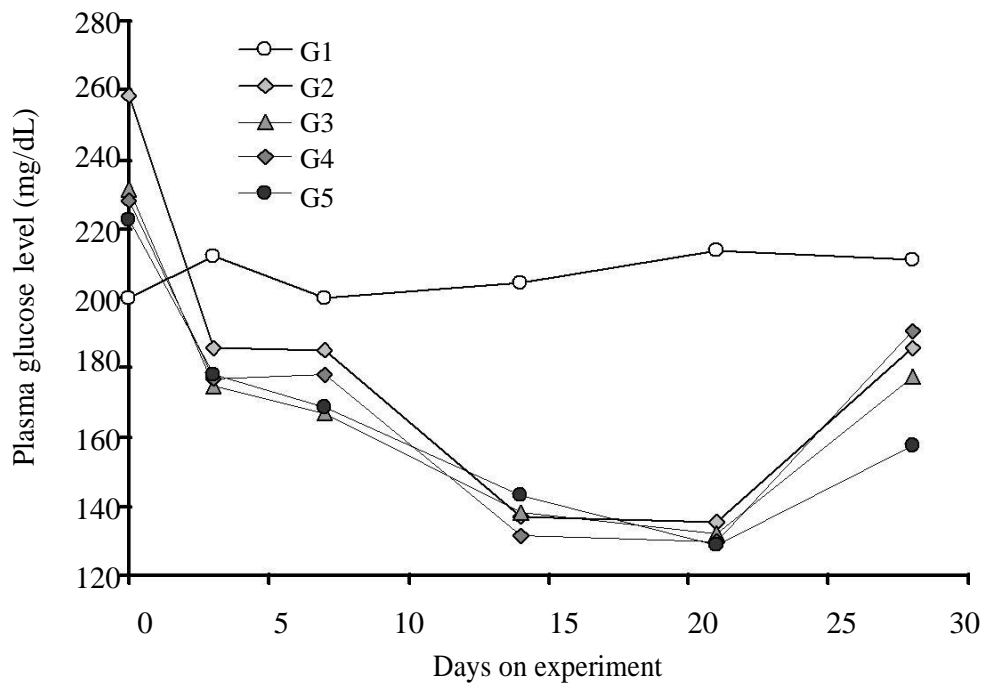
## DISCUSSION

This study has demonstrated the effect of aqueous crude

resin extracts from *C. swynnertonii* on various haematological and biochemical parameters in chickens. Only chickens receiving higher resin doses (G4 and G5) showed signs of adverse effects including dullness and loose faeces. This was an indication that extended administration of high doses of the *C. swynnertonii* resin extract could be detrimental to the gastrointestinal tract (GIT) of chickens. Similar observations have been reported in rats (Scott, 2005) and humans (Olivier, 2009) who noted increased mucus production in the intestinal tract following treatment with resin from some *Commiphora* species. These findings suggest that the resin can stimulate production of mucus in the GIT. The negative effect of resin on body weight of chickens was clearly evident and was dose-dependent. The weight reduction effect has been associated with reduction in plasma cholesterol and glucose levels through



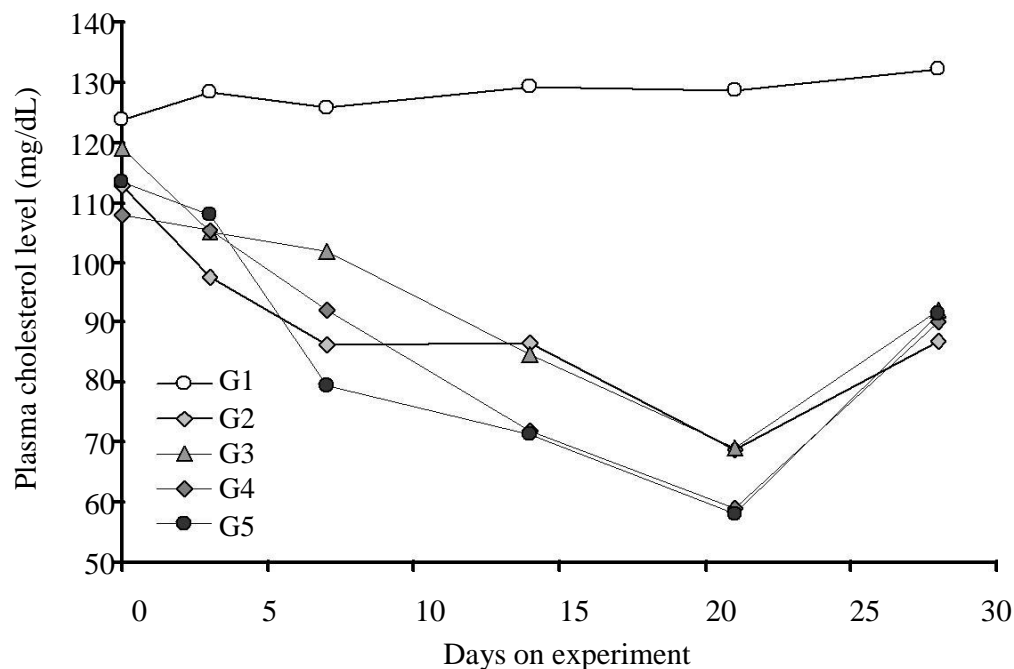
**Figure 1.** Changes in body weight following resin administration for 14 days with different levels of *C. swynnertonii* resin extract.



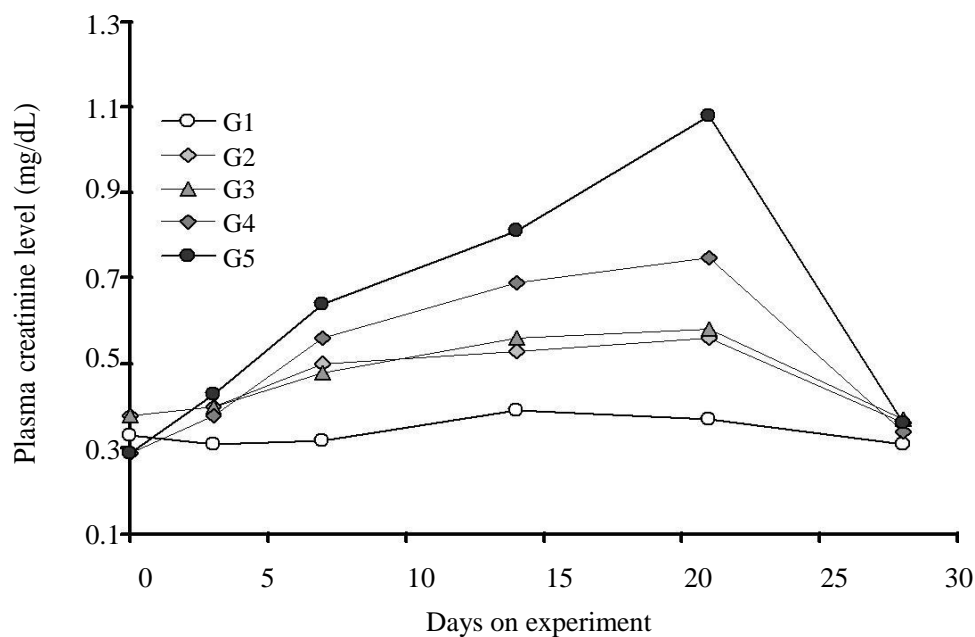
**Figure 2.** Total plasma glucose profiles of chickens following administration of *C. swynnertonii* resin extract.

stimulation of thyroid hormone (T3 and T4) function, thus interfering with basal metabolic rate leading to loss of body weight (Scott, 2005). Thyroid hormones (T3),

stimulates the production of RNA polymerase I and II, and therefore, increases the rate of protein synthesis and potentiates the effects of the  $\beta$ -adrenergic receptors on



**Figure 3.** Total plasma cholesterol profiles of chickens following administration of *C. swynnertonii* resin extract.



**Figure 4.** Plasma creatinine profiles of chickens following administration of *C. swynnertonii* resin extract.

the metabolism of glucose (Guyton and John, 2006). Also thyroid hormones stimulate the breakdown of cholesterol and increases the number of low-density lipoprotein (LDL) receptors, thereby increasing the rate of lipolysis

(Guyton and John, 2006). In the current study, the metabolite reduction caused by the resin extract could be a probable cause of decreased body weight in chickens.

Administration of the resin to chickens affected some of

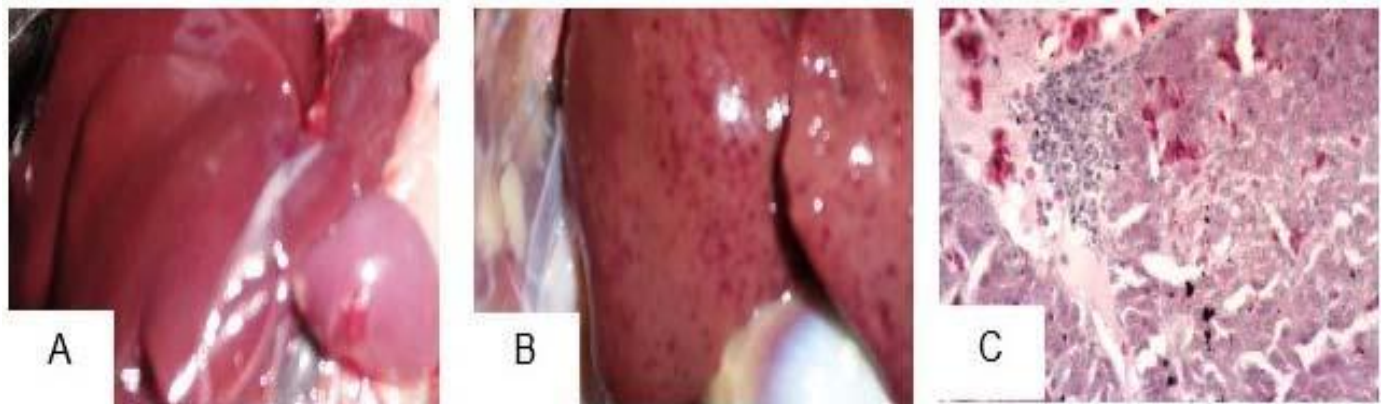

the haematological parameters in different ways. PCV, differential WBC count (neutrophils and eosinophils) were not affected. Hb, total RBC count, MCH and MCHC decreased with increasing concentration of the resin. This significant decrease could be as a result of the presence of saponins in the resin. Saponins are known to cause red blood cell breakdown by dissolving their membranes; hence, causing haemolytic crisis (Kayser et al., 2002) and suppression of growth and differentiation of RBC in the bone marrows (Elekofehinti et al., 2012). Similar studies with other *Commiphora* spp. reported no significant changes in PCV, Hb, MCH, MCHC and RBC counts in experimental animals (El-Naggar, 2011). The significant increase in lymphocytes and monocytes counts indicated that *C. swynnertonii* has the ability to activate the defence mechanism in chickens. In this study, increased mononuclear cell infiltration was observed in liver and kidney. A study by Haffor (2009) reported an increase in leucocytes proliferation in Wistar albino rats following an oral administration of resin from *Commiphora molmol*. The significant dose dependent reduction in plasma glucose and total cholesterol can be referred to as hypoglycemic and hypocholesteremic effect, respectively. Other studies using various *Commiphora* spp. also reported hypoglycemic effect in Wistar rats (Sheela and Augusti, 1992; Helal et al., 2006; Goji et al., 2009). This effect has been associated with increased glycogen intake by increasing insulin level. Helal et al. (2006) attributed the hypoglycemic effect of *Commiphora* with a decreased production of glucose precursors in the liver, suggesting the usefulness of this therapy in treating non-insulin dependent diabetes mellitus. Another interesting finding in the current study was the reduction in total plasma cholesterol following administration of the resin. Other studies involving differential cholesterol determination revealed reduction in total cholesterol, low density lipoprotein cholesterol (LDL-c) and very low density lipoprotein (VLDL-c) cholesterol at the same time elevating the high density lipoprotein cholesterol (HDL-c) (Wang et al., 2004; Adebayo et al., 2006; Bellamkonda et al., 2011). The exact mechanism through which the *Commiphora* resin reduces plasma cholesterol levels is yet to be known. Some *Commiphora* spp. (e.g., *Commiphora mukul*) contains some compounds such as guggulsterone, which act by antagonizing the effect of the nuclear farnesoid  $\times$  receptor (F $\times$ R) (Tu et al., 2000; Thrall et al., 2006). The F $\times$ R is a key transcriptional regulator for the maintenance of cholesterol and bile acid dynamics. F $\times$ R has been shown to regulate cholesterol metabolism by binding directly to the chenodeoxycholic acid (CDCA), a primary bile acid, which mediates the feedback suppression by bile acids of cholesterol 7- $\alpha$ -hydroxylase, thus limiting the enzyme in bile acid biosynthesis from cholesterol (Wu et al., 2002). Secondly, the F $\times$ R participates in the activation of intestinal bile acid binding protein, which is involved in the enterohepatic circulation of bile acids.

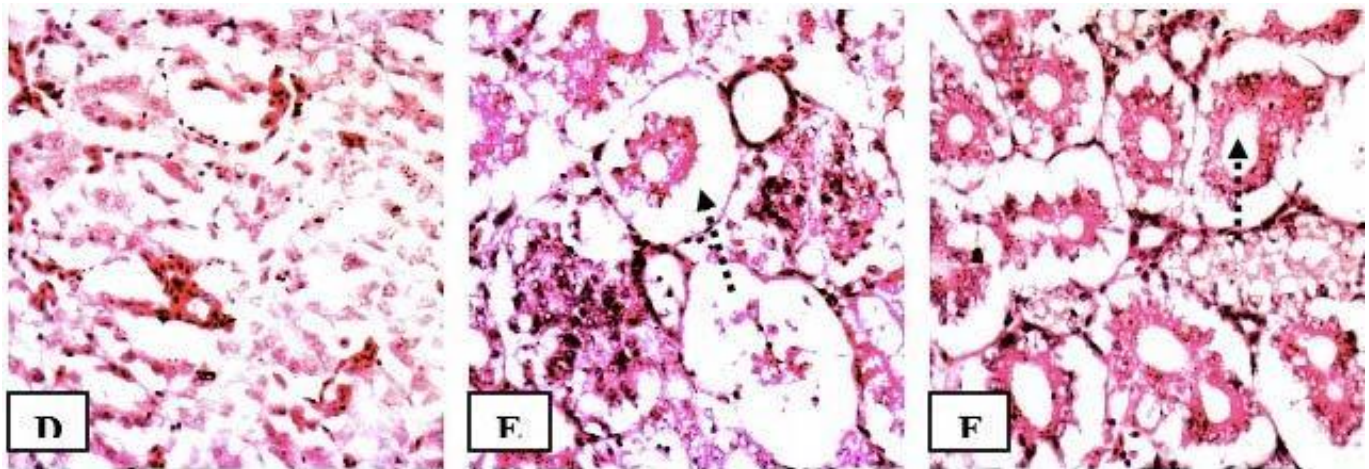
Thus, according to Tu et al. (2000), F $\times$ R constitutes a potential therapeutic target that can be modulated to enhance the removal of cholesterol from the body. Another possible mechanism is through the presence of ketosteroid, an active compound of *C. mukul* which acts by stimulating the thyroid gland and has also been found to increase the activity of catecholamine and dopamine-p-decarboxylase that are involved in lowering plasma cholesterol (Wang et al., 2004; Wang et al., 2006). Some secondary plant metabolites such as coumarin, flavonoid, terpenoid, arginine and glutamic acids have been shown to confer glucose and cholesterol lowering effects in various experimental animal models (Akah and Okafor, 1992; Marles and Farnsworth, 1995). The significant hypoglycemic and hypocholesteremic effect observed in the current study can therefore be explained by the fact that *C. swynnertonii* contain remarkable amounts of terpenoids and flavanoids. Terpenoids and flavanoids appear to be involved in the stimulation of the  $\beta$ -cells and the subsequent secretion of preformed insulin (Goji et al., 2009; Bellamkonda et al., 2011).

Liver enzymes transaminases (AST and ALT) are often used as specific markers of active hepatic injury and represent markers of hepatocellular necrosis (Davern and Scharschmidt, 2002; Thrall et al., 2006). Whereas ALT activity is primarily localised in the liver and largely specific for parenchymal diseases (Gatsing et al., 2005; Thrall et al., 2006), AST activity is present in a wide variety of tissues including heart, skeletal muscle, kidney, brain and the liver (Gatsing et al., 2005). In the current study, liver transaminases (ALT and AST) levels increased to the maximum peak by day 21-post treatment before decreasing significantly to levels similar to pre-treatment values. Similar studies reported no change in levels of AST and ALT activity after treating rats with *C. molmol* for 24, 48 and 72 h (Rao et al., 2001; Aliyu et al., 2007). In this study, it was observed that prolonged use of resin extract caused liver damage (mottling appearance, Plate 1) thus led to increased concentrations of liver enzymes in the blood.

The effect of the resin in kidneys was assessed through determination of plasma creatinine levels, which usually increase when there is significant renal impairment (Thrall et al., 2006). Thus, the significant increase in plasma creatinine levels observed in chickens in groups G4 and G5 after 14 days of treatment concur with the noticeable damage of the renal cortices and glomeruli as seen in histopathological sections (Plate 2). Similar findings were reported by Aliyu et al. (2007); that is, prolonged use of ethanolic leaf extracts from *Commiphora africana* caused noticeable damage to the cortex and glomerulus in rats. The significant increase in creatinine at high doses may possibly be due to some regenerative mechanisms by the kidney in response to the effect of resin extract. It is known that for any markers of kidney function (creatinine or uric acid) to significantly appear in blood, about 75% of the nephrons must have.



**Plate 1.** Liver: (A) normal liver (untreated group, G1); (B) mottled appearance (G5); (C) nuclear cell infiltration at  $\times 40$  magnification, H&E stain (G5).



**Plate 2.** Kidney sections: normal kidney; (E) glomerular and hydropic tubular degeneration; (F) cystic luminal and cortical dilatation ( $\times 40$  magnification, H&E Stain).

been damaged (Boyd, 1983; Thrall et al., 2006). This suggests that administration of high doses of *C. swynnertonii* resin could be detrimental to kidneys.

In conclusion, this study has demonstrated that chickens can tolerate oral administration of *C. swynnertonii* resin at doses less than 750 mg/kg body weight whereby haematological parameters tested and liver functions were not significantly affected. Administration of higher doses had negative effects on liver, kidney and lung functions, which included acute glomerulonephritis and pulmonary congestion, respectively. The observed hypoglycemic, hypocholesteremic and body weight lowering effect were interesting findings, which can be used as a template for further research in humans. Further studies on the resin extract are needed to isolate the bioactive component(s), elucidate its exact mechanism(s) of action and validate its uses in the chickens and other animal species.

## ACKNOWLEDGEMENTS

The study has been funded by the Carnegie Rise - AFNNET Program. The authors wish to thank the many people who assisted at various stages of the work, including botanists and laboratory technicians at the Faculty of Veterinary Medicine.

## Conflict of Interest

The authors declare that they have no conflict of interest. Experiments were carried out in accordance with ethical guidelines of the Sokoine University of Agriculture.

## REFERENCES

Adebayo AH, Aliyu R, Gatsing D, Garba IH (2006). The effects of



- ethanolic leaf extract of *Commiphora africana* (Burseraceae) on lipid profile in rats. *Inter. J. Pharm.* 2:618-622.
- Adnan M, Hussain J, Tahir Shah MT, Shinwari ZK, Ullah F, Bahader A, Naeem Khan N, Khan AL, Watanabe T (2010). Proximate and nutrient composition of medicinal plants of humid and sub-humid regions in north-west Pakistan. *Res. J. Med. Plant* 4:339-345.
- Akah PA, Okafor CL (1992). Blood sugar lowering effect of *Veronia amygdalina* (Del) in an experimental rabbit model. *Phytother. Res.* 6:171-173.
- Aliyu R, Adebayo AH, Gatsing D, Garba IH (2007). The effects of leaf extract pharmacology of *Commiphora africana* (Burseraceae) on rat liver and kidney function. *J. Pharmacol. Toxicol.* 2:373-379.
- Bakari GG, Max RA, Mdegela RH, Phiri EC, Mtambo MMA (2013). Effect of resinous extract from *Commiphora swynnertonii* (Burrt) on experimental coccidial infection in chickens. *Trop. Anim. Health Prod.* 45:455-459.
- Bakari GG, Max RA, Mdegela RH, Phiri ECJ, Mtambo MMA (2012a). Antiviral activity of crude extracts from *Commiphora swynnertonii* (Burrt) against Newcastle disease virus *in ovo*. *Trop. Anim. Health Prod.* 44(7):1389-93.
- Bakari GG, Max RA, Mdegela RH, Phiri ECJ, Mtambo MMA (2012b). Effect of crude extracts from *Commiphora swynnertonii* (Burrt) against selected microbes of animal health importance. *J. Med. Plants Res.* 6(9):1795-1799.
- Bellamkonda R, Karuna R, Sreenivasa RS, Ramesh BK, Ramatholisamma P, Appa RC, Saralakumari D (2011). Antihyperglycemic and antioxidant activities of alcoholic extract of *Commiphora mukul* gum resin in streptozotocin induced diabetic rats. *Pathophysiology* 18(4):255-61.
- Boyd JW (1983). The mechanisms relating to increase in plasma enzymes and isoenzymes in diseases of animals. *Vet. Clin. Pathol.* 12:9-24.
- Bush BM (1991). Total protein, albumin and globulin. Interpretations of Laboratory Results for Small Animal Clinicians. Blackwell Scientific Publications. pp. 238-255.
- Davern TL, Scharschmidt BF (2002). Biochemical Liver Function Tests. In: Sleisenger and Fordtrans' Gastrointestinal and Liver Disease Pathophysiology. Diagnosis and Management, Feldman M.L.C. Friedman and M.H. Sleisenger (Eds.). 7th Edn. Elsevier Science, USA.
- Dharmananda S (2003). Myrrh and frankincense, spiritual significance. The Holy Bible, as quoted by Dharmananda, 2003. Internet J. 2:1-6.
- Drury RAB, Wallington EA (1976). Carleton's Histological Techniques, 4th Edition, Oxford University Press, London.
- Elekofehinti OO, Adanlawo IG, Fakoya A (2012). Solanum anguivi saponins inhibit basal erythropoiesis in rattus novergicus. *Asian J. Pharm. Health Sci.* 2:416-419.
- El-Mahmood AM, Ameh JM (2007). In vitro antibacterial activity of *Parkia biglobosa* (Jacq.) root bark extract against some microorganisms associated with urinary tract infections. *Afr. J. Biotech.* 6:1272-1275.
- EL-Naggar SA (2011). Lack of the beneficial effects of Mirazid (*Commiphora molmol*) when administered with Chemotherapeutic Agents on Ehrlich Ascetic Carcinoma Bearing Mice. *Adv. Biol. Res.* 5:193-199.
- Fudge AM (2000). Avian complete blood count, in Laboratory Medicine: Avian and exotic pets, 1st Edn. Saunders. pp. 9-18.
- Gatsing D, Aliyu R, Kuate JR, Garba IH, Jaryum KH (2005). Toxicological evaluation of the aqueous extract of *Allium sativum* bulbs on laboratory mice and rats. *Cameroon J. Exp. Biol.* 1:39-45.
- Goji ADT, Dikko AAU, Bakari AG, Mohammed A, Tanko Y (2009). Evaluation of the Effect of Aqueous-ethanolic Stem Bark Extract of *Commiphora africana* on Blood Glucose Levels of Alloxan Induced Diabetic Wistar Rats. *Asian J. Med. Sci.* 1:18-21.
- Guyton AC, John E (2006). Textbook Of Medical Physiology (11th ed.). Philadelphia: Elsevier Inc. ISBN 0-7216-0240-1.
- Haffor AA (2010). Effect of *C. molmol* on leucocyte proliferation in relation to histological alteration before and during healing from injury. *King Saud. J. Biol. Sci.* 17:139-146.
- Helal EGE, Mahmoud A, El-Badawy EE, Kahwash AA (2006). Effect of *Commiphora myrrha* extract on some physiological parameters and histological changes in diabetic albino rats. *Egyptian J. Hosp. Med.* 148-162.
- Kaoneka B, Mollel M Lyatuu F (2007). Leaf essential oil composition and tick repellency activity of *Commiphora swynnertonii* Burtt. *J. Biol. Res.* 8:213-216.
- Kayser O, Albrecht F, Kiderlen Croft SL (2002). Studies in Natural Product Research. Atta-Ur-Rahman (edition). Freie University, Berlin.
- Marles RJ, Farnsworth NR (1995). Antidiabetic plants and their active constituents. *Phytomedicine* 2:137-187.
- Olivier R (2009). *Helicobacter pylori* bacteria: Tools for Eradication. The Original Internist. Vol. 16, No. 2.
- Rao RM, Khan ZA, Shah AH (2001). Toxicity studies in mice of *Commiphora molmol* oleo-gum resin. *J. Ethnopharmacol.* 76(2):151-4.
- Scott AM (2005). Gum guggul and some of its steroidal constituents. Review of toxicological literature prepared for national toxicology program (NTP) and National Institute of Environmental Health Sciences (NIEHS). National Institutes of Health U.S Department of Health and Human Services. Research Triangle Park, North Carolina. pp. 18-21.
- Sheela CG, Augusti KT (1995). Antiperoxide effects of S -allyl cysteine sulphoxide isolated from *Allium sativum* Linn and gugulipid in cholesterol diet fed rats. *Indian J. Exp. Biol.* 33:337-41.
- Thrall AM, Baker CD, Campbell TW, DeNicola D, Martin JF, Lassen ED, Alan R, Weiser G (2006). Veterinary Hematology and Clinical Chemistry. Blackwell Publishing. pp. 21, 301-307, 355-380.
- Trinders P (1969). Determination of glucose in blood using glucose oxidase with an alternative oxygen acceptor. *J. Clin. Pathol.* 22(2):158-61.
- Tu H, Okamoto AY, Shan B (2000). FXR a bile acid receptor and biological sensor. *Trends Cardiovasc. Med.* 10(1):30-5.
- Wang J, Bo R, Xu L, Mi Z, Wang C (2006). A CARB-like  $\beta$ -lactamase gene from a multiple-drug-resistant *Pseudomonas aeruginosa* clinical isolate in China. *J. Med. Microbiol.* pp. 1609-1610.
- Wang XJ, Greiberger G, Ledinski G, Kager B, Paigenand G, Jurgen (2004). The hypolipidemic natural product, *Commiphora mukul* and its component guggulsterone inhibit oxidative modification of LDL. *Atherosclerosis* 172:239-249.
- World Health Organization (WHO) (2006). Blood Safety and Clinical Technology: Guidelines on Standard Operating Procedures for Clinical Chemistry.
- World Health Organization (WHO) (2007). Guidelines for assessing quality of herbal medicines with reference to contaminants and residues. WHO Library Cataloguing-in-Publication Data. pp. 1-5.
- Wu J, Xia C, Meier J, Li S, Hu X, Lala DS (2002). The hypolipidemic natural product guggulsterone acts as an antagonist of the bile acid receptor. *Mol. Endocrinol.* 16(7):1590-7.