

Case Report

Extensive multifocal tuberculosis verrucosa cutis in a young child

Muhammad Hasibur Rahman^{1*} and Nazma Parvin Ansari²

¹Department of Dermatology and VD Community Based Medical College, Bangladesh.

²Department of Pathology of Dermatology and VD Community Based Medical College, Bangladesh.

Accepted 22 September, 2018

Although there has been increasing number of tuberculosis cases throughout the world, but multifocal cutaneous tuberculosis accounts to be a very rare manifestation. An interesting study report inform us of one such case of multifocal tuberculosis verrucosa cutis in a 12-year old male child encountered with a typical presentation alike in the absence of any primary tuberculous focus and extensive involvement.

Keywords: Multifocal, tuberculosis verrucosa cutis (TVC), young child.

INTRODUCTION

Tuberculosis an ancient early century malady caused by *Mycobacterium tuberculosis*. In recent times cutaneous tuberculosis constitutes only a small proportion of extra pulmonary tuberculosis. Tuberculosis verrucosa cutis (TVC) is also recognized as warty tuberculosis (Wolff and Tappeiner, 1999), anatomist's wart or prosector's wart and is characterized by the presence of verrucous plaque-like lesions. It is naturally initiated due to direct inoculation of the organism into the skin of a previously infected patient. In addition to this hematogenous (Irgang, 1955) tumor-like (Iizwa et al., 1991) and exuberant granulomatous (Wong et al., 1968) forms have been assessed and described. In Bangladesh, the incidence of cutaneous tuberculosis is increasing considerably as we are experiencing in our clinical practice. This is however very rare in developed countries. Clinically, the lesion begins to appear as a small papule, which later becomes hyperkeratotic, resembling a wart. The lesion enlarges by peripheral expansion, with or without central clearing, sometimes reaching to about several centimeters or more in diameter. There may be fissuring purulent exudates of the surface. They are found seldom to ulcerate and heal spontaneously. Histologically, there is pseudoepitheliomatous hyperplasia of the epidermis and hyperkeratosis. Suppurative and granulomatous inflammations are

observed to persist in the upper and mid-dermis, sometimes perforating through the epidermis. The number of acid-fast bacilli found is consistently scanty. The tuberculin test is however strongly positive.

CASE REPORT

A 12-year old male child is presented with multiple well defined verrucous plaques spread all over his extremities bilaterally and asymmetrically distributed for a contracting period of 2 years. Initially, the lesion started at the instep of the right foot as an itchy papule, which later enlarged into a painful form of verrucous plaque. After one year of attack the patient took homeopathic medicine for the remedy. Getting no relief and when he noticed similar lesions developing on the lateral aspect of the same foot as well as the opposite foot, legs and arms his parents brought their boy to our clinic for treatment.

These lesions were progressively developing and increasing in size, shape and number. On examination, multiple hyperkeratotic verrucous, oozy plaques were noticed to locate on the inner dorsal and lateral aspect of both legs (Figures 3 and 4) and arms (Figures 1 and 2). The size of the lesions varied and ranged from 2 × 3 to 12 × 5 cm. The base of the lesion was not fixed to deeper structures and satellite papules were present around the plaques. Yellowish staining of the plaque as found in the section is the lesion. There was no regional

*Corresponding author. E-mail: dr_cosmoderma@yahoo.com.

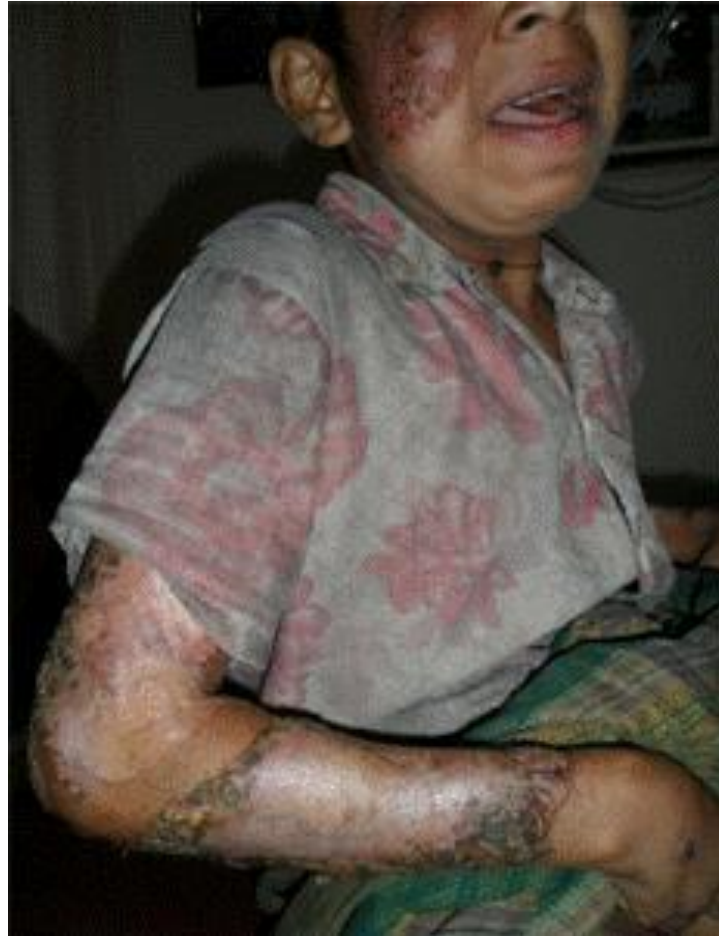

Figure 1. Showing TVC lesions over the right arm, forearm and cheek.

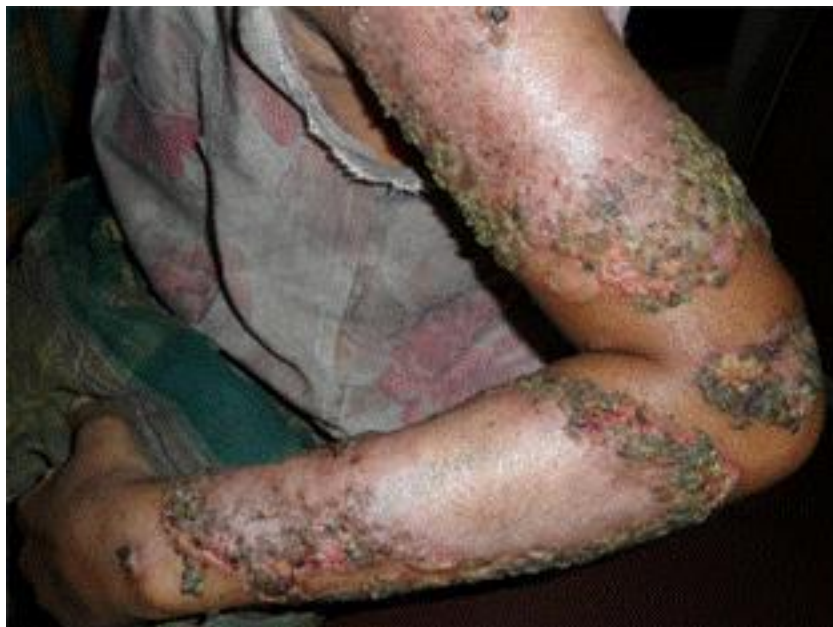

Figure 2. Showing TVC lesions over left arm and forearm.

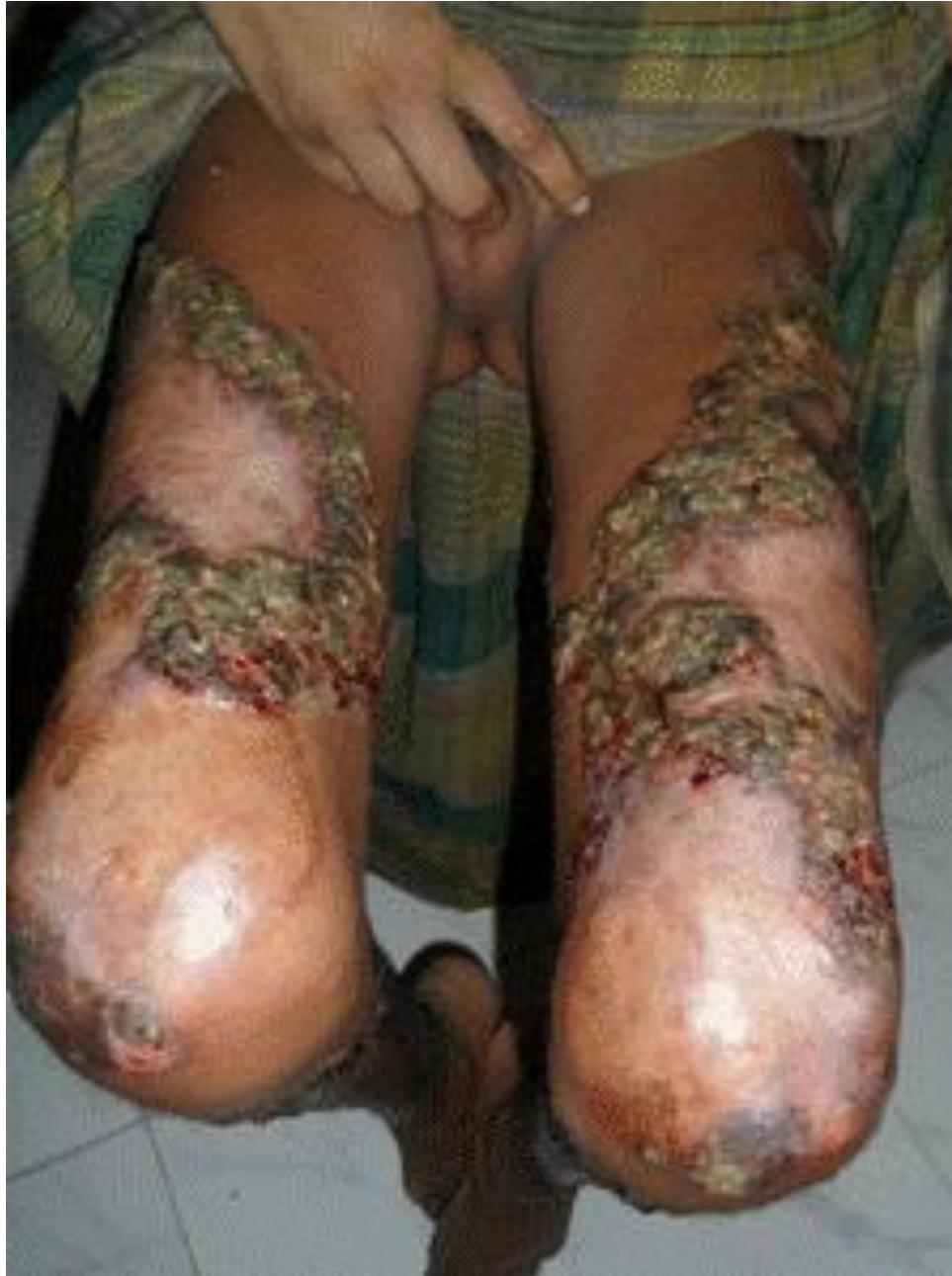

Figure 3. Showing TVC lesions over both lower limbs.

lymphadenopathy. Systemic examination did not reveal any abnormality. The mother of the boy patient gave information about family history of positive PTB association of the father. Routine blood investigations and chest radiographs were within normal limits. Mantoux test measurement indicated 17×15 mm in size. Ten percent potassium hydroxide smear preparation was negative for fungus. Radiographs of the foot showed only soft-tissue swelling without bony involvement. Biopsy from the foot lesion was consistent with TVC, with marked hypertrophy of the epidermis and mid-dermal

granuloma with Langhan's giant cells (Figure 5). Treatment was started with isoniazid, rifampicin, ethambutol, and pyrizinamide, daily for 2 months, followed by isoniazid and rifampicin for another 4 months. Within three months, lesions flattened out and at the end of 6 months all lesions got completely resolved.

DISCUSSION

TVC or Warty tuberculosis, a verrucous form of skin

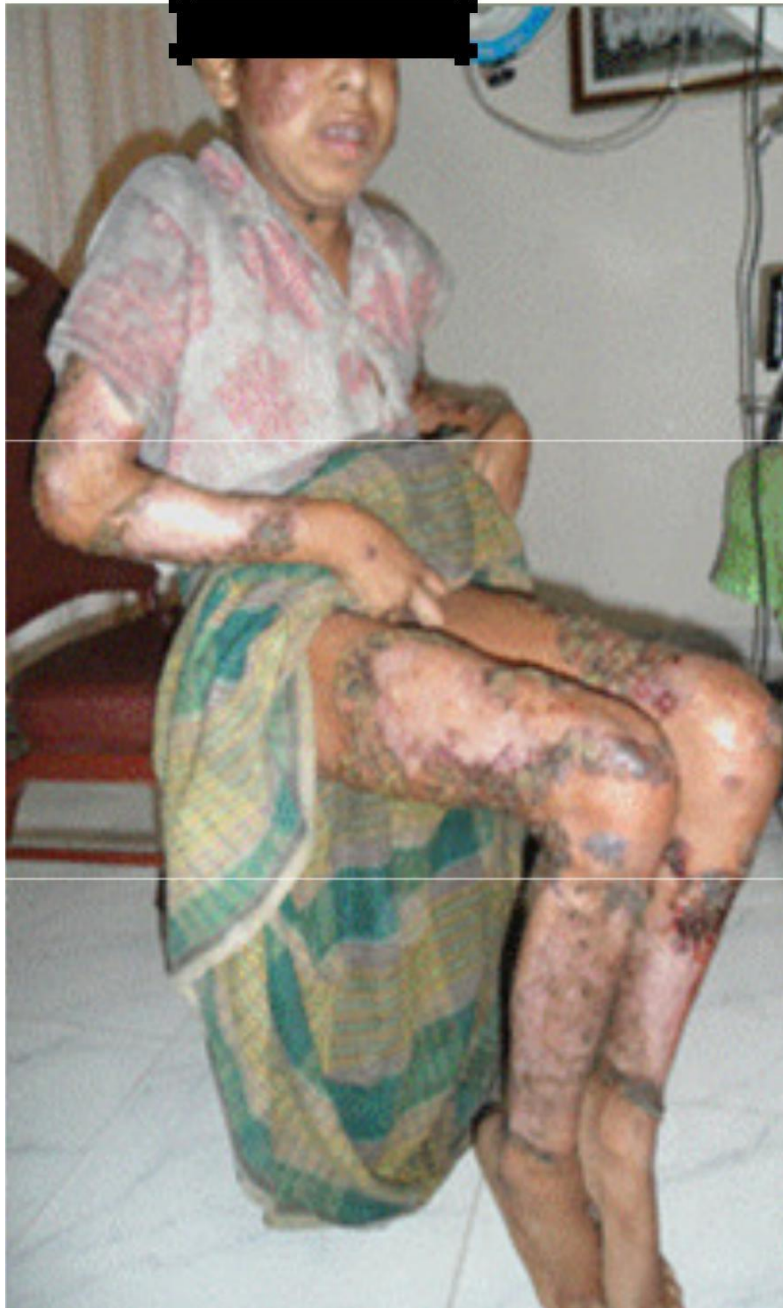

Figure 4. Showing TVC over all limb and face.

tuberculosis occurs in a previously sensitized individuals due to exogenous reinfection with *M. tuberculosis* and *Mycobacterium bovis* (Wolff and Tappeiner, 1999). The symptoms of mycobacterial infections depend mainly on the route of transmission, the pathogenicity and drug resistance of the bacteria, the immune status of the host and various local factors. Adult males are reported to be most commonly affected (Irgang, 1955), probably because they are more usually involved in heavy manual work and liable to chances of trauma infection, thus

facilitating the entry of *M. tuberculosis*. In our study the patient is a bare footed child who is very much habituated to play in the ground field, jungle and ponds favoring the association of risk of acquiring infection.

Percutaneous transmission leading to cutaneous tubercular manifestations is now becoming very common (Chowdhury et al., 2000; De Jong and van, 2000). Cutaneous tuberculosis is perceived to form a continuous spectrum, with lupus vulgaris and TVC at one end and scrofuloderma and tuberculosis cutis orificialis at the

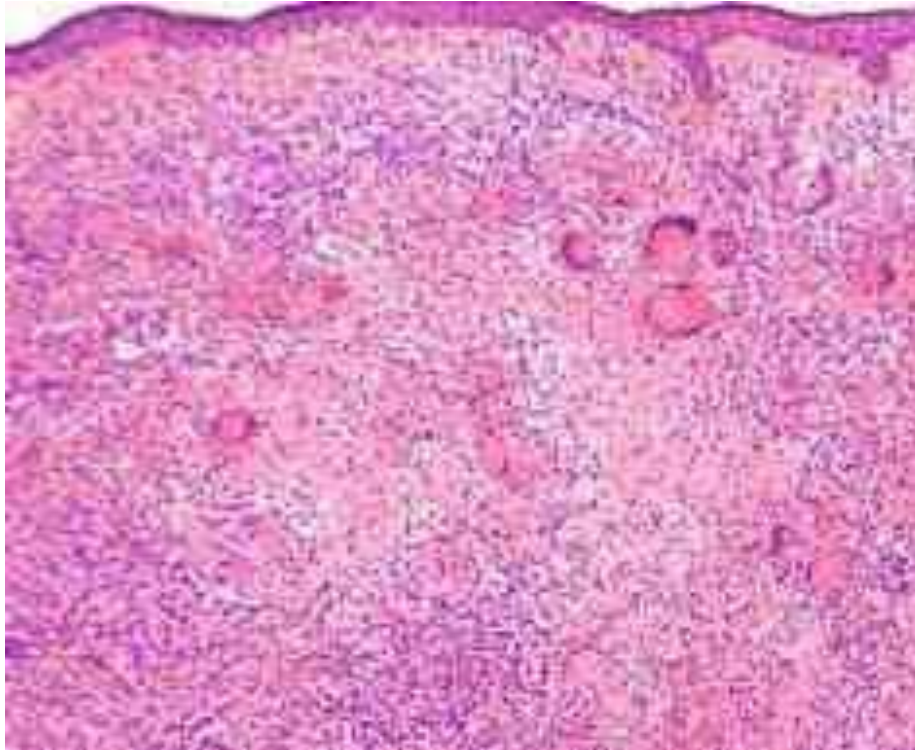


Figure 5. Showing granuloma in mid dermis of TVC.

other, corresponding to a declining cell-mediated immunity across the spectrum. TVC, a verrucous form of cutaneous tuberculosis results from inoculation of tubercle bacilli into the skin of a previously infected patient with moderate to high degree of immunity (Sehgal and Wagh, 1990). The diagnosis of TVC is based on history, evolution of the disease, cardinal morphological features and histopathological characteristics. Pulmonary tuberculosis can spread to distant or contiguous sites. The most common site of occurrence is the lower limbs and this can be substantiated by a clinico-pathological and epidemiological study as suggested by Padmavathy et al. (2008). However, multifocal cutaneous lesions without any other tubercular focus in the body are quite rare. Prasad et al. (2002) reported a similar case with multifocal involvement (Prasad et al., 2002). Such a case is even more unusual as there was no evidence of immune competence. The multifocal pattern of the disease in our patient may be attributed to multiple sites of entry of the organism, without any pulmonary focus. Moreover, the patient tends cattle herd; this may probably explain the possible anthro-zoonotic (Montali et al., 2001) transmission of the organism, integrated with the unnoticed micro-trauma. Pus may sometimes be expressed from the fissures or soft area (Wilkinson, 1986). The boy patient also exhibited the same features. Regional lymphadenopathy is not often associated with TVC (Kakakhel and Petter, 1989). Our patient did not

have any lymphadenopathy. There is a strong tendency to verrucous hyperplasia and fibrosis in lesion partly due to the immunological background and partly due to the specific terrain of the acral skin (Mehregan, 1986). Similar verrucous plaques were observed in our patient. TVC lesions have frequently been reported in patients on the hands in the European and on the lower limbs in the Eastern countries (Singh, 1974). Here in this report, in a Bangladeshi boy the lesions were found to occur spreading over all limbs as precisely reported in the interesting clinical appearance. Combination of different types of cutaneous TB has been reported, but this multifocal involvement of the same limb is a rare entity. Such rare occurrences and insidious nature of infection should prompt the dermatologist to look into other associations and address the persistence of potential infection.

REFERENCES

- Chowdhury MM, Varma S, Howell S, Holt PJ, Statham BN (2000). Facial cutaneous tuberculosis: an unusual presentation. *Clin. Exp. Dermatol.*, 25: 48-50.
- De Jong JW, van Altena R (2000). Non-respiratory tuberculosis with *Mycobacterium tuberculosis* after penetrating lesions of the skin: five case histories. *Int. J. Tuberc. Lung Dis.* 4: 1184-1187.
- Iizwa O, Aiba S, Tagami H (1991). Tuberculosis verrucosa cutis in a tumour like form. *Br. J. Dermatol.*, 125: 79-80.
- Irgang S (1955). Ulcerative cutaneous lesions in sarcoidosis. *Br. J. Dermatol.*, 67: 255-260.

- Kakakhel KV, Petter F (1989). Cutaneous tuberculosis. *Int. J. Dermatol.*, 1989, 28: 355-362.
- Mehregan AH (1986). Predominantly mononuclear granulomas. In *Pinkus guide to dermatohistopathology*, 4th ed. Connecticut: Appleton century crofts. pp. 254-255.
- Montali RJ, Mikota SK, Cheng LI (2001). *Mycobacterium tuberculosis* in zoo and wildlife species. *Rev. Sci. Tech.*, 20: 291-303.
- Padmavathy L, Lakshmana Rao L, Pari T, Ethirajan N, Krishnaswamy B (2008). Lupus vulgaris and tuberculosis verrucosa cutis: Clinicopathological study of 71 patients. *Indian J. Tub.*, 55: 203-209.
- Prasad PVS, Ambujam S, Paul EK, Krishnasamy B, Veliath AJ (2002). Multifocal tuberculosis verrucosa cutis: An unusual presentation. *Indian J. Tub.*, 49: 229.
- Sehgal VN, Wagh SA (1990). Cutaneous tuberculosis: Current concepts. *Int. J. Dermatol.*, 29: 237-252.
- Singh G (1974). Lupus vulgaris in India. *Ind. Dermatol. Venereol. Leprol.* 40: 257-260.
- Wilkinson DS (1986). Tuberculosis of Skin. In Rook A, Wilkinson DS, Ebling E.J.G. *Text book of Dermatology* 3rd ed. Delhi: CBS Publishers and distributors. pp. 667-700.
- Wolff K, Tappeiner G (1999). Mycobacterial disease. Tuberculosis and a typical mycobacterial infection. In Freedberg IM Eisen AZ, Wolff K et al Editors. *Dermatology in general medicine*, 5th ed. New York: Mc Graw Hill. 2: 2152-2180.
- Wong KO, Lee KP, Chin SF (1968). Tuberculosis of the skin in Hong Kong. *Br. J. Dermatol.*, 80: 424-4299.