

Case Report

A Case report on retroperitoneal soft tissue (sarcomas. Liposarcoma) type of Liposarcoma tumor

Daron Ismail Sunal

Bezmialem Vakif University Gastroenterology Clinic, Turkey.

Accepted 17 October, 2016

Liposarcoma is the most common tumor type of retroperitoneal soft tissue sarcomas. Liposarcoma is a malignant tumor of mesenchymal origin in which the bulk of tumor differentiates into adipose tissue. A 50 year old male patient was presented at our clinic with abdominal mass and pain. Abdominal ultrasonography, computed tomography (CT) and magnetic resonance imaging (MRI) showed a huge retroperitoneal mass. Hematologic, biochemistry and tumor markers were normal. Then, he was operated. He was reported as case well-differentiated retroperitoneal liposarcoma that weighted 3.000 g.

Key words: Liposarcoma, retroperitoneal mass, sarcoma.

INTRODUCTION

Soft tissue sarcomas are rare and account for less than 1% of all newly diagnosed malignancies. One-third of malignant tumors arising in the retroperitoneum is sarcomas. Liposarcoma is the most common soft tissue sarcoma and retroperitoneal sarcoma. The major sites of liposarcoma are the extremities, retroperitoneum and inguinal region. Liposarcomas are remarkable because of their frequently large size and they are among the largest tumors. Liposarcomas are most commonly seen in adults aged 40 to 50 years. Liposarcoma accounts for at least 20% of all sarcomas in adults and up to 41% of all retroperitoneal sarcomas. Here we present the case of a huge retroperitoneal liposarcoma.

CASE REPORT

A 50-year old male was referred to our hospital from a local clinic. There was abdominal distention, pain and

palpable mass. We found that his abdomen was markedly distended. Abdominal ultrasonography, computed tomography (CT) and magnetic resonance imaging (MRI) showed a huge retroperitoneal mass in the left abdominal cavity (Figure 1). He was operated. The tumor was located in the left retroperitoneal cavity and invaded along between iliac arteries. The tumor was measured 23 × 17 × 11 cm, 7 × 4 × 3 cm, 4.5 × 3.5 × 2.5 cm and weighed 3.000 g. On the basis of the histopathological finding, the tumor was diagnosed as a differentiated liposarcoma of the retroperitoneum (Figure 2).

DISCUSSION

Liposarcomas are one of the most common soft tissue sarcomas. They frequently occur in the extremities and the retroperitoneum of adults. They are well known for their large size. In the published literature, a 32 kg

*Corresponding author: E-mail: daron.sunal@hotmail.com

Author(s) agreed that this article remain permanently open access under the terms of the Creative Commons Attribution License 4.0 International License

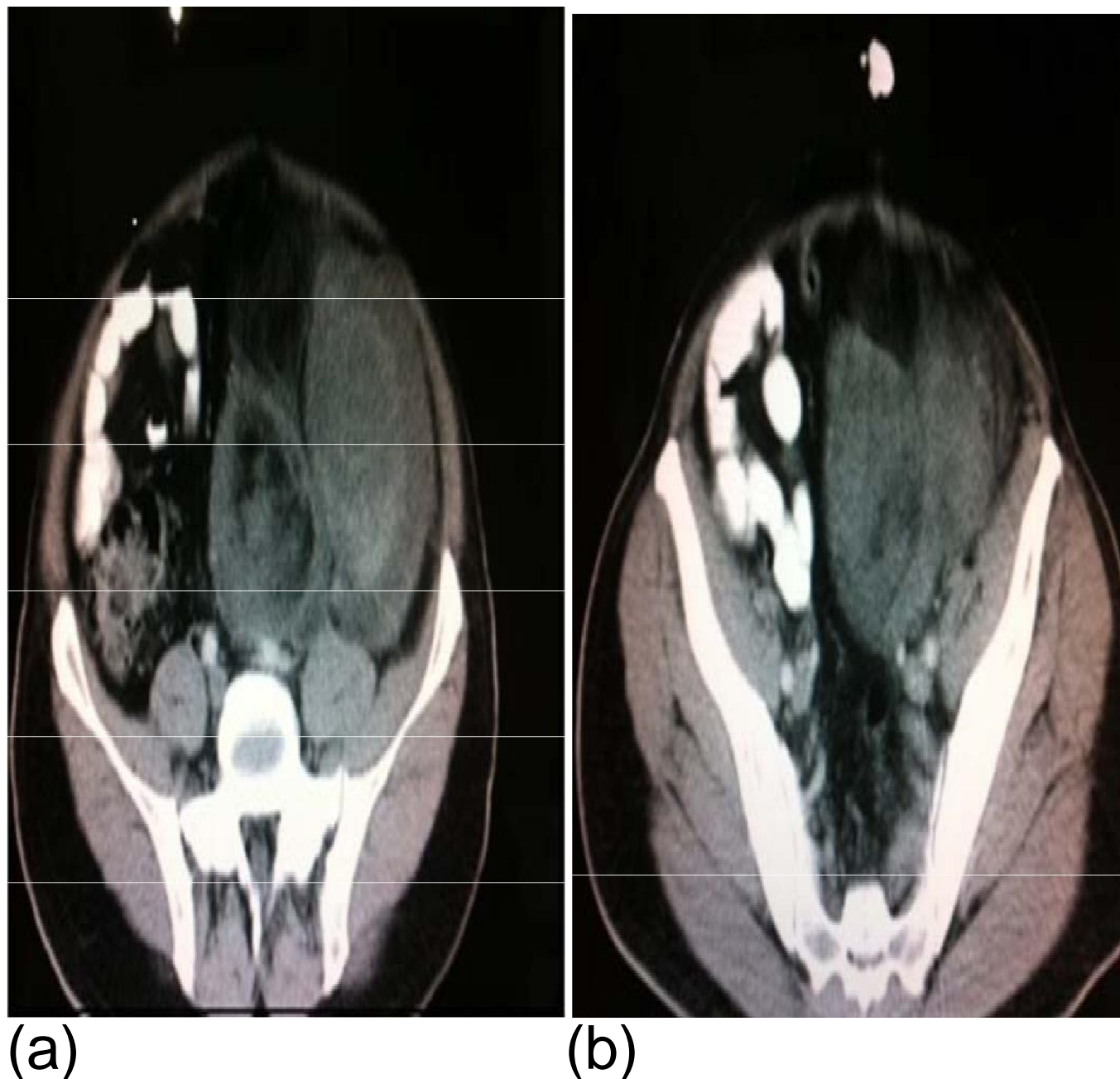
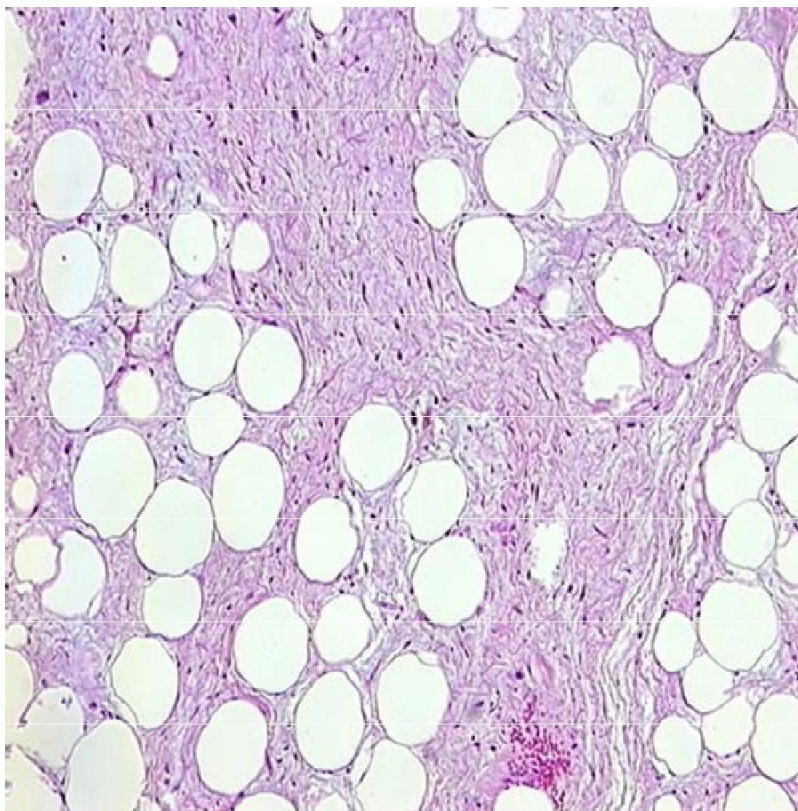


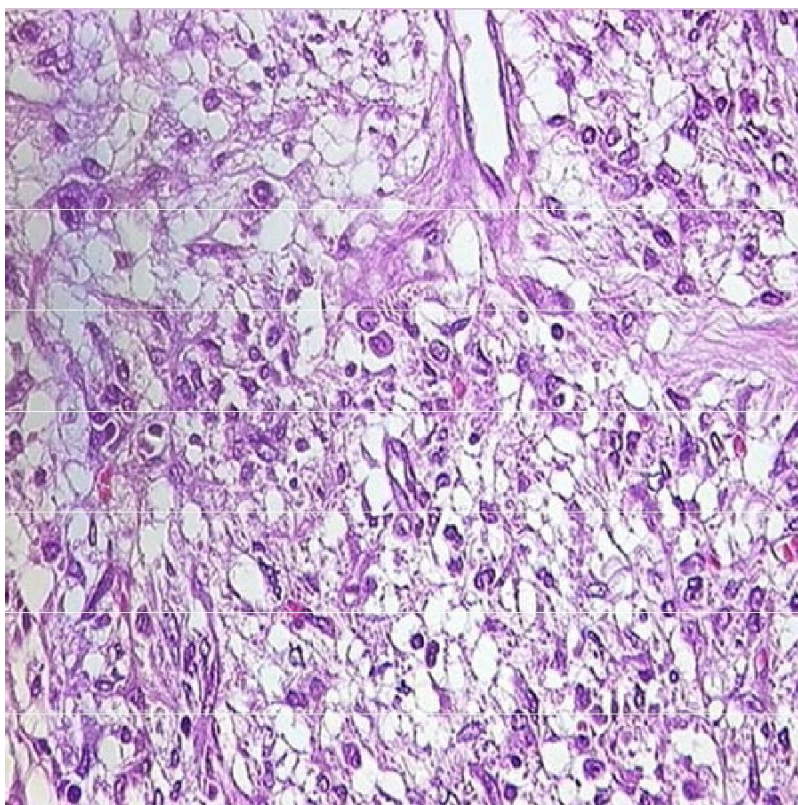
Figure 1. Computed tomography demonstrates a large mass located at retroperitoneal space.

liposarcoma have been reported. Retroperitoneal liposarcomas are difficult to detect early because the symptoms of these tumors are nonspecific; the tumors can thus grow slowly in the retroperitoneal space, reaching a considerable size before being diagnosed (Inoue et al., 2005; Bradley and Caplan, 2002; Hashimoto et al., 2010). The present case was 3.000 g. Liposarcomas are histologically classified into five groups: myxoid liposarcomas, well differentiated liposarcomas, round cell (poorly differentiated myxoid liposarcomas),

pleomorphic liposarcomas and differentiated liposarcomas. Myxoid liposarcomas are the most common type, found in approximately 50% of cases, followed by well differentiated liposarcomas that account for approximately 25% of cases. The clinical characteristics are closely related to histological type. Well differentiated liposarcomas and myxoid liposarcomas have a good prognosis. (Herrera-Gomez et al., 2008; Fernandez-Ruiz et al., 2010; Antinori et al., 2002; Goertz et al., 2009). Our case was reported by a well differentiated liposarcoma.



(a)



(b)

Figure 2. Pathological examination revealed a well differentiated liposarcoma (HE, original magnification $\times 400$).

Presently, we are monitoring a case of post-op which was done 2 months ago.

Conflict of interest

Authors declare that there are no conflicts of interest.

REFERENCES

- Antinori A, Antonacci V, Magistrelli P (2002). Giant retroperitoneal liposarcoma. *Am. J. Surg.* 184(1):56-7.
- Bradley JC, Caplan R (2002). Giant retroperitoneal sarcoma: a case report and review of the management of retroperitoneal sarcomas. *Am. Surg.* 68(1):52-6.
- Fernandez-Ruiz M, Rodriguez-Gil Y, Guerra-Vales JM, Manrique-Municio A, Moreno-Gonzalez E, ColinaRuizdelgado F (2010). Primary retroperitoneal liposarcoma: clinical and histological analysis of ten cases. *Gastroenterol. Hepatol.* 33(5):370–6.
- Goertz RS, Lenfers BH, Goertz GH (2009). Huge liposarcoma of the left retroperitoneum. *Am. J. Surg.* 197(6):e59-e60.
- Hashimoto Y, Hatakeyama S, Tachiwada T, Yoneyama T, Koie T, Kamimura N (2010). Surgical treatment of a giant liposarcoma in a Japanese man. *Adv. Urol.* 2010:943073.
- Herrera-Gomez A, Ortega-Gutierrez C, Betancourt AM, Luna-Ortiz K (2008). Giant retroperitoneal liposarcoma. *World J. Surg. Oncol.* 6:115.
- Inoue K, Higaki Y, Yoshida H (2005). Giant retroperitoneal liposarcoma. *Int. J. Urol.* 12(2):220-2.